

PATHOLOGY REPORTING OF BREAST DISEASE

A Joint Document Incorporating the Third Edition
of the NHS Breast Screening Programme's
Guidelines for Pathology Reporting in Breast Cancer Screening
and the Second Edition of The Royal College of Pathologists'
Minimum Dataset for Breast Cancer Histopathology

NHSBSP Publication No 58
January 2005

Published by the NHS Cancer Screening Programmes jointly with The Royal College of Pathologists

NHS Cancer Screening Programmes

The Manor House
260 Ecclesall Road South
Sheffield S11 9PS

Tel: 0114 271 1060

Fax: 0114 271 1089

Email: nhs.screening@sheffield-ha.nhs.uk

Web site: www.cancerscreening.nhs.uk

The Royal College of Pathologists

2 Carlton House Terrace
London SW1Y 5AF

Tel: 020 7451 6700

Fax: 020 7451 6701

Email: info@rcpath.org

Web site: www.rcpath.org

© NHS Cancer Screening Programmes and The Royal College of Pathologists 2005

The contents of this document may be copied for use by staff working in the public sector but may not be copied for any other purpose without prior permission from the NHS Cancer Screening Programmes and The Royal College of Pathologists. Permission to reproduce the Minimum Dataset for Breast Cancer Histopathology should be sought from The Royal College of Pathologists. Permission to reproduce any other content should be sought from the NHS Cancer Screening Programmes.

ISBN 1 84463 015 3

A copy of this publication is available as a PDF on the NHS Cancer Screening Programmes website (www.cancerscreening.org.uk) and The Royal College of Pathologists' website (www.rcpath.org).

Further copies of this publication are available from the Department of Health Publications Orderline quoting NHSBSP Publication No 58.

Tel: 08701 555 455

Fax: 01623 724 524

Email: doh@prolog.uk.com

Typeset by Prepress Projects Ltd, Perth (www.prepress-projects.co.uk)

Printed by Charlesworth, Wakefield

CONTENTS

	Page No
WRITING GROUP	vii
PREFACE	1
1. SPECIMEN HANDLING	5
2. SURGICAL HANDLING	6
3. LABORATORY HANDLING	8
4. DIAGNOSTIC LOCALISATION BIOPSIES	9
5. THERAPEUTIC WIDE LOCAL EXCISIONS	10
5.1 Method 1: serial slicing perpendicular to the medial–lateral plane	10
5.2 Method 2: serial slicing perpendicular to the superficial–deep plane	12
5.3 Method 3: radial block examination, with or without shave margin	12
6. RE-EXCISION SPECIMENS	14
7. MASTECTOMY SPECIMENS	15
8. PATHOLOGICAL EXAMINATION OF LYMPH NODES	16
8.1 Background	16
8.2 Lymph node sample specimens, including sentinel node samples	16
8.3 Axillary clearance specimens	16
8.4 Sentinel lymph node biopsy samples	17
8.5 Additional techniques for the examination of lymph nodes	17
8.6 Frozen section examination	18
9. NHSBSP HISTOPATHOLOGY REPORTING FORM	19
10. MINIMUM DATASET FOR BREAST CANCER HISTOPATHOLOGY	22
11. RECORDING BASIC INFORMATION	24
11.1 Pathologist	24
11.2 Date	24
11.3 Side	24
11.4 Specimen radiograph seen?	24
11.5 Mammographic abnormality present in specimen?	24
11.6 Histological calcification	24

Pathology Reporting of Breast Disease

11.7	Specimen type	24
11.8	Specimen weight	24
11.9	Benign/malignant lesion present	24
12.	CLASSIFYING BENIGN LESIONS	25
12.1	Complex sclerosing lesion/radial scar	25
12.2	Fibroadenoma	25
12.3	Papilloma	29
12.4	Periductal mastitis/duct ectasia (plasma cell mastitis)	33
12.5	Fibrocystic change	34
12.6	Sclerosing adenosis	35
12.7	Solitary cyst	37
12.8	Columnar cell change	37
12.9	Other (specify)	40
13.	CLASSIFYING EPITHELIAL PROLIFERATION	41
13.1	Not present	41
13.2	Present without atypia	41
13.3	Present with atypia (ductal)	44
13.4	Atypical lobular hyperplasia and lobular carcinoma in situ (in situ lobular neoplasia)	44
14.	CLASSIFYING MALIGNANT NON-INVASIVE LESIONS	50
14.1	Ductal carcinoma in situ	50
14.2	Paget's disease of the nipple	59
14.3	Microinvasive carcinoma	59
15.	CLASSIFYING INVASIVE CARCINOMA	61
15.1	No special type	61
15.2	Pure special type	61
15.3	Mixed tumour type	61
15.4	Morphological type	61
15.5	Other malignant tumour	69
15.6	Not assessable	69
16.	TUMOUR SIZE	70
16.1	Invasive tumour size	70
16.2	In situ (DCIS) size	72
16.3	Whole tumour size	72
16.4	Tumour extent	72
17.	HISTOLOGICAL GRADE	74
17.1	Tubule/acinar formation	76
17.2	Nuclear atypia/pleomorphism	77
17.3	Mitoses	78
17.4	Overall grade	79

Pathology Reporting of Breast Disease

18.	VASCULAR INVASION	81
19.	LYMPH NODE STAGE	83
19.1	Reporting and definitions of micrometastatic disease and isolated tumour cells	83
20.	EXCISION MARGINS	84
20.1	Invasive carcinoma	84
20.2	DCIS and invasive carcinoma with an extensive in situ component	84
21.	STEROID RECEPTORS	86
21.1	Recommendations for steroid receptor testing	86
21.2	Principles	86
21.3	Scoring	87
21.4	Ductal carcinoma in situ	87
21.5	Testing predictive factors	87
22.	COMMENTS/ADDITIONAL INFORMATION	88
23.	FINAL HISTOLOGICAL DIAGNOSIS	89
24.	SNOMED CODING	90
	REFERENCES	91
	APPENDIX 1: UPDATED RCPATH GUIDELINES ON WORKLOAD FOR BREAST PATHOLOGY	97
	APPENDIX 2: WIDE BORE NEEDLE BIOPSY FORM	99
	APPENDIX 3: SYNOPTIC REPORTS	103
	APPENDIX 4: INDEX FOR SCREENING OFFICE PATHOLOGY SYSTEM	109
	APPENDIX 5: TNM CLASSIFICATION OF TUMOURS OF THE BREAST	114
	APPENDIX 6: UPDATED RECOMMENDATIONS FOR HER2 TESTING IN THE UK	118
	APPENDIX 7: QUALITY ASSURANCE FOR OESTROGEN RECEPTORS AND PROGESTERONE RECEPTORS	127
	APPENDIX 8: QUALITY ASSURANCE FOR HUMAN EPIDERMAL GROWTH FACTOR RECEPTOR 2 (HER2) IMMUNOHISTOCHEMICAL ASSAYS	129
	APPENDIX 9: NOTTINGHAM PROGNOSTIC INDEX	131
	APPENDIX 10: SUGGESTED SNOMED CODES FOR BREAST PATHOLOGY	132

WRITING GROUP

Chairman	Professor IO Ellis University of Nottingham Department of Histopathology Nottingham City Hospital Hucknall Road Nottingham NG5 1PB	Professor of Cancer Pathology
Deputy Chairman	Dr SE Pinder Histopathology Department Addenbrooke's Hospital Hills Road Cambridge CB2 2QQ	Consultant Pathologist
	Dr L Bobrow Addenbrooke's Hospital Hills Road Cambridge CB2 2QQ	Consultant Pathologist
	Dr ID Buley Department of Cellular Pathology (Level 1) The John Radcliffe Hospital Headington Oxford OX3 9DU	Consultant Pathologist
	Dr J Coyne Withington Hospital West Didsbury Manchester M20 8LR	Consultant Pathologist
	Dr JJ Going University Department of Pathology Glasgow Royal Infirmary 84 Castle Street Glasgow G4 0SF	Consultant Pathologist
	Dr S Humphreys Department of Cellular Pathology Preston Hall Hospital Maidstone Kent ME20 7NH	Consultant Pathologist
	Dr B Jasani Department of Pathology University of Wales College of Medicine Heath Park Cardiff CF4 4XN	Consultant Pathologist

Pathology Reporting of Breast Disease

Professor S Lakhani Consultant Pathologist
Breakthrough Toby Robins Breast Cancer Research Centre
Institute of Cancer Research
Mary Jean Mitchell Green Building
Chester Beatty Laboratories
Fulham Road
London SW3 6JB

Dr J Lowe Consultant Pathologist
Bradford Royal Infirmary
Duckworth Lane
Bradford
West Yorkshire BD9 6RJ

Mr K Miller UK NEQAS for Immunocytochemistry
Department of Histopathology
University College London Medical School
University Street
London WC1E 6JJ

Dr A Rhodes UK NEQAS for Immunocytochemistry
Consultant Pathologist
Department of Histopathology
University College London Medical School
University Street
London WC1E 6JJ

Professor RA Walker Consultant Pathologist
Department of Histopathology
University of Leicester
School of Medicine
Robert Kilpatrick Clinical Sciences Building
Leicester Royal Infirmary
PO Box 65
Leicester LE2 7LX

Dr CA Wells Consultant Pathologist
St Bartholomew's Hospital
West Smithfield
London EC1A 7BE

The authors of this document are members of the Guidelines Working Group of the National Coordinating Committee for Breast Pathology, which is responsible for pathology quality assurance for the National Health Service Breast Screening Programme (NHSBSP) and for preparation of minimum dataset standards in breast cancer histopathology for The Royal College of Pathologists. Dr A Rhodes, Mr K Miller and Dr B Jasani are members of the UK National External Quality Assessment Scheme for Immunocytochemistry (NEQAS) and were coopted to the working group to assist with the sections on quality assurance of immunocytochemical predictive testing for hormone receptors and HER-2.

Membership of the National Coordinating Group for Breast Screening Pathology:

Dr SZ Al-sam, Dr N Anderson, Dr L Bobrow, Dr ID Buley, Dr D Coleman, Professor E Connolly, Dr NS Dallimore, Professor IO Ellis (Chairman), Dr SA Hales, Professor A Hanby, Dr S Humphreys, Dr F Knox, Mrs S Kodikara, Professor S Lakhani, Dr J Lowe, Dr J Macartney, Dr S Moss, Dr R Nash, Dr D Parham, Dr N Patel, Mrs J Patnick, Dr SE Pinder, Dr CM Quinn, Dr AJ Robertson, Dr J Shrimankar, Professor RA Walker, Dr CA Wells, Mr R Winder.

Acknowledgement

The contribution of Professor CW Elston for providing some of the photomicrographs is gratefully acknowledged.

PREFACE

Reduction in mortality from breast cancer requires that all professional groups involved perform to the highest standards. The quality of pathological services is of the utmost importance. Pathologists almost invariably make the definitive diagnoses of breast cancer, and additional features of in situ and invasive carcinomas that have prognostic significance are also required to determine the most appropriate management for individual patients. Thus, the management of patients with breast disease and breast cancer detected through mammographic screening or symptomatic presentation depends heavily on the quality of the pathology service. This document has been produced jointly by the NHS Breast Screening Programme (NHSBSP) and The Royal College of Pathologists (RCPath) and represents the third edition of the guidelines produced by the NHSBSP for pathology reporting in breast cancer screening and the second edition of the minimum dataset for breast cancer histopathology produced by The Royal College of Pathologists. It serves to give guidance and recommendations on all aspects of pathology examination of breast lesions and is relevant to both screen detected and symptomatic disease. Accurate pathology diagnoses and the provision of prognostically significant information are important to ensure that patients are managed appropriately and that breast services and the NHSBSP are effectively monitored and evaluated. A standard set of data from each patient, using the same terminology and diagnostic criteria, is essential to achieve these objectives.

These guidelines aim to encourage the use of common terminology and definitions of breast disease and to standardise methods of classification of breast cancer.

The reporting forms and guidance in the following pages were produced after extensive and lengthy consultation with participating pathologists. They define the RCPath minimum set of data for reporting breast cancer histopathology and complementary NHSBSP data for breast screening pathology. The standards of reporting symptomatic cancers are the same as those for reporting screen detected lesions. The minimum dataset for reporting of breast cancer histopathology has been implemented for the following reasons:

1. Certain features of invasive carcinoma (size, type, grade, vascular invasion, lymph node status) have been shown to be related to clinical outcome. Consequently, these features may be important in:
 - a. deciding on the most appropriate treatment for patients, including the extent of surgery and the use and choice of adjuvant therapy
 - b. monitoring breast screening programmes, the success of which is reflected by more favourable prognostic features of the cancers detected
 - c. monitoring changing patterns of disease, particularly by cancer registries.

2. Classification of ductal carcinoma in situ (DCIS) together with reporting of margins of excision and size have been shown to be related to the probability of recurrence after local excision and may influence the use of mastectomy or adjuvant radiotherapy.
3. Close correlation of radiological and histopathological features is essential to ensure that mammographically detected lesions have been sampled and accurately diagnosed.

This document also serves to provide guidance for pathologists when participating in the UK External Quality Assessment (EQA) Scheme for Breast Screening Histopathology. Two of the major objectives for pathology quality assurance (QA) in the NHSBSP are to improve the consistency of diagnoses made by pathologists and to improve the quality of prognostic information in pathology reports. In order to achieve these objectives, a standardised reporting proforma and supporting guidelines for reporting breast pathology have been developed jointly by the RCPATH and the NHSBSP. The national breast screening EQA scheme was set up in parallel both as an educational tool and to investigate the level of consistency that pathologists involved in the screening programme could achieve in reporting breast lesions. Clearly, this is determined not only by the performance of the pathologists themselves but also by the methodology they use. Problems identified can be addressed through various initiatives, the success of which may be evaluated in further rounds of the scheme.

Four main situations have been encountered to date with respect to diagnostic consistency:

1. Consistency is very high, including diagnosing in situ and invasive carcinoma (and certain distinctive subtypes) and uncomplicated benign lesions.
2. Consistency is suboptimal, but could be improved by making the guidelines more detailed and explicit; only histological grading fell into this category.
3. Consistency could be improved, but only by changing the system of classification, eg DCIS grade.
4. No improvement in consistency could be achieved, including diagnosing atypical hyperplasia and reporting vascular invasion. The former has remained refractory to a major initiative involving significant refinement of diagnostic criteria and much greater explicitness of guidance. No specific measures have yet been taken to improve the latter.

This edition of the guidelines serves to update previous editions in light of the above observations from the EQA scheme and feedback from pathologists. Sections dealing with classification of lesions or reporting of prognostic factors where lack of concordance has been identified have been revised. Specifically, the document improves on guidance for macroscopic examination and sampling of breast specimens and provides better guidance on reporting epithelial proliferative lesions and in situ carcinoma, tumour type, histological grade, tumour size and vascular invasion. In addition, guidance is now included on reporting

prognostic indices and predictive factors such as hormone receptor and HER-2 status.

Finally, recent assessment of pathologists' workload is described, based on the complexity of macroscopic as well as microscopic examination. The updated RCPATH recommendations for breast specimens are included in Appendix 1.

1. SPECIMEN HANDLING

Some general guidelines for specimen handling, both in the operating theatre and in the laboratory, can be described. The type of surgical procedure will be influenced by whether a preoperative diagnosis has been achieved and, if so, the nature of the diagnosis (benign or malignant). If no preoperative diagnosis has been made, the surgical procedure will be in the form of a diagnostic open biopsy. Surgical QA guidelines indicate that such specimens should be confined to removal of the lesion with a minimal amount of surrounding tissue in order to avoid leaving a cosmetic defect. These specimens should generally weigh less than 20 g and should, therefore, be weighed in the pathology laboratory. The lesion may be impalpable, and resection may require image guided localisation using wire, dye or radioisotope. **Frozen section examination is inappropriate for diagnosis of screen detected lesions.**

If a benign surgical diagnosis has been made, the operation will be undertaken at the patient's request for removal. Such resections should be confined to removal of the lesion with a minimal amount of surrounding tissue to avoid leaving a cosmetic defect. In some centres, where available, vacuum assisted large bore needle resection is being used for benign lesion resection.

If a malignant diagnosis has been made, the surgical procedure will be influenced by the nature, size and location of the lesion as well as by patient choice. The technique chosen for pathological examination of these specimens requires knowledge of the surgical method used and the anatomical boundaries of the resection. Whichever technique is used, the methodology should enable production of the breast cancer minimum dataset information.

2. SURGICAL HANDLING

- It is anticipated that lesions will be resected according to a defined surgical protocol. If the surgical resection differs from the protocol, eg if dissection does not extend to the deep fascia or skin when this is the norm, this should be clearly indicated on the request form.
- The surgeon should orientate cancer resection specimens. Each unit should establish a code of orientation using either different lengths of suture or metal staples/clips or ink. The code should be anatomically relevant and assist in accurate evaluation of the specimen and its margins. The nipple extension/direction of the nipple should be separately marked.
- If more than one piece of tissue is removed, it should be made clear how the samples are orientated with respect to each other in order to simplify assessment of the size of the lesion and distance to margins.
- After surgical excision of the specimen, it is appropriate for localisation resections to be radiographed. In some centres, wide local excision specimens are also radiographed. This allows confirmation of the presence of the abnormality and also its location in the specimen, thus facilitating immediate re-excision if the specimen is close to a margin. The radiographs should ideally be reported by the breast radiologist. The specimen radiographs must, however, be available to the pathologist so that he/she can be certain of the nature of the lesion, ie mass, calcification, etc. The pathologist can therefore also assess where the lesion is situated in the specimen in order to facilitate histological sampling.
- The specimen should be sent immediately to the pathology laboratory, ideally in the fresh state. If this is not possible, it should be immediately placed in a fixative whose volume is at least twice that of the specimen size. In the latter circumstance, and by arrangement with the pathologist, consideration should be given to allowing the surgeon to make a controlled single or cruciate pair of incisions into

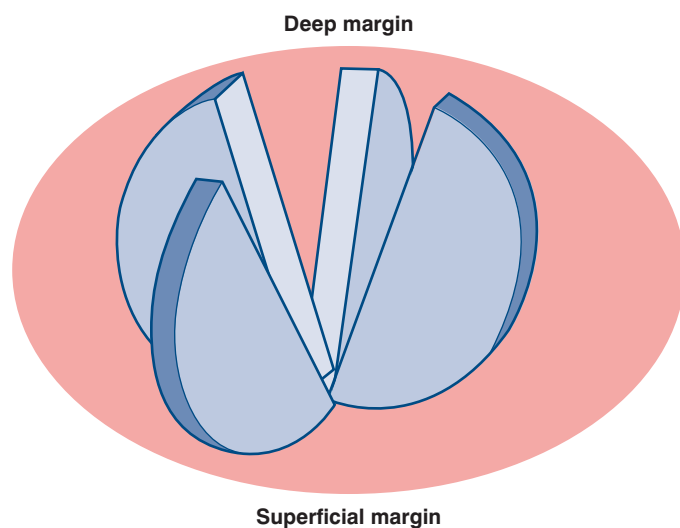


Figure 1 Incision of tumour from deep aspect to allow formalin penetration.

the lesion, thus preserving the integrity of key margins while allowing immediate penetration of fixative (Figure 1). The incision should be made from the posterior aspect. The benefits of rapid fixation (good tissue morphological conservation with preservation of mitotic figures and retention of proteins such as the oestrogen receptor) in general outweigh the desire to preserve the specimen intact prior to examination by the pathologist. This is most important in mastectomy specimens for which formalin penetration can be particularly poor and can result in tumour autolysis with consequent effects on mitotic count as a component of histological grade and also the assessment of vascular invasion.

3. LABORATORY HANDLING

- Once received in the laboratory, the entire surface of the specimen should be inked so that the margins of excision can be easily determined. This can be performed by prior removal of surface lipid by dipping the specimen in alcohol and drying and then applying an appropriate pigment such as Indian ink, Alcian blue, dyed gelatine or a multiple ink technique. Indian ink can be fixed after painting using 10% acetic acid.
- Good fixation is vital to preserve the morphological detail. This is particularly relevant for the diagnosis of some difficult intraductal epithelial proliferations and classification and prognostication in malignancy (eg histological grade, type and vascular invasion). Specimens must be placed in sufficient formalin (twice the volume of the specimen) or other appropriate fixative inside an appropriately sized and shaped container either before or, preferably, after receipt by the laboratory. Incision of the specimen as described in Chapter 2 is beneficial in achieving rapid fixation of the tumour in larger specimens.

4. DIAGNOSTIC LOCALISATION BIOPSIES

- The specimen should be weighed and measured and then, usually, serially sliced at intervals of approximately 3–5 mm.
- Cases where block selection is required (ie those that are not embedded in their entirety) will benefit from specimen slice x-ray examination, particularly those with an impalpable mammographic lesion such as microcalcification. This enables blocks to be taken from the areas corresponding to the mammographic abnormality, as well as any other suspicious areas identified.
- The sites of sampling can be marked on the specimen x-ray or the x-ray of specimen slices by using a white wax (Chinagraph) pencil or other marker.
- The sampling technique and the number of blocks taken are clearly dependent on the size of the specimen and the size of the abnormality. If the specimen is small, it is often best to block and examine all of the tissue. Samples of approximately 30 mm or less in maximum dimension should be completely sliced, embedded and examined histologically.
- For larger specimens, sampling should be adequate to determine accurately the size of the lesion. Sampling should include the extremes of the mammographic abnormality and adjacent tissue in order to avoid underestimation of size. This is particularly important with cases of DCIS as it is recognised that mammographic size may be an underestimate of true tumour size.
- If specimens are sent as more than one piece of tissue, it can be impossible to measure the absolute extent of the lesion. In these cases, it is appropriate to take a pragmatic approach and to measure the maximum size in each piece of tissue and add the dimensions to give an estimated total size. If, however, the orientation of the specimens can be determined, the true size can be ascertained more reliably.

5. THERAPEUTIC WIDE LOCAL EXCISIONS

- It is usual for the surgeon when performing a therapeutic operation to take all of the tissue from the subcutaneous aspect to the pectoral fascia. It is essential that the pathologist is informed if the usual surgical protocol has not been undertaken as this will affect the optimum specimen handling methodology.
- Particularly for therapeutic excisions of calcification or where there is a preoperative diagnosis of DCIS without invasion, it is helpful if the surgeon marks the nipple duct margin; DCIS tracks down towards the nipple and, in this plane, can be some distance from the obvious area of microcalcification.
- The specimen should be weighed and measured in three dimensions.
- The technique for sampling the abnormality will vary somewhat according to type of sample and specimen size and also according to pathologist/laboratory preference, therefore a degree of flexibility is required. Several options are available. Whichever is utilised, as an absolute minimum, the information for the breast cancer minimum dataset, including accurate measurement of size and detailed examination of the margin status and distance to margins, must be provided. Three preferred methods for handling these samples are described in Figures 2–4.
- A few units use large blocks to embed the entirety of segmental excisions, but the proper processing of these can delay the reporting of the case and storage may also be problematic; many units therefore take a pragmatic approach to the problem.
- This method is commonly used for examination of impalpable lesions, such as microcalcification, as it enables specimen slice radiographic mapping of the specimen and provides a high level of confidence that the lesion has been accurately and adequately sampled.

5.1 Method 1: serial slicing perpendicular to the medial–lateral plane (Figure 2)

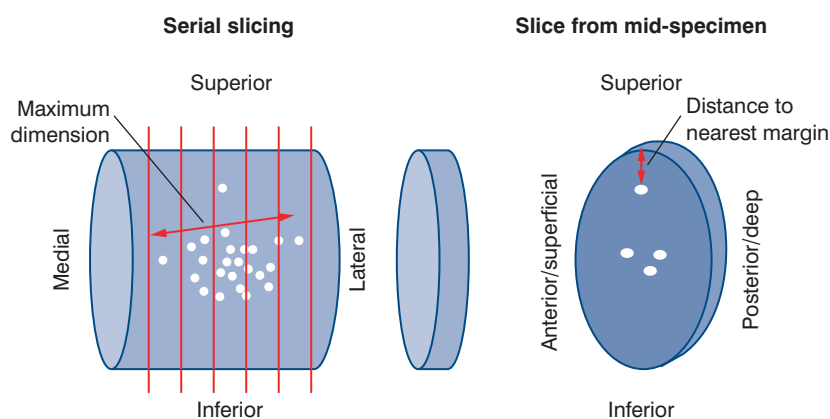


Figure 2 Method 1: serial slicing perpendicular to the medial–lateral plane.

- The specimen can be sliced either before fixation or after fixation and marking of the excision margins. The specimen is sliced at intervals of approximately 3–5 mm, usually perpendicular to the medial–lateral axis in the anterior–posterior plane.
- These specimens may benefit from specimen slice radiographic examination, but this may not be absolutely essential for all samples, eg mass lesions. Where microcalcification is the principal feature by which the lesion was detected, slicing and re-radiographing the specimen slices will enable blocks to be taken most accurately from the areas corresponding to the mammographic abnormality as well as from any other suspicious areas identified. The sites of sampling can be marked on the specimen radiograph for radiological–pathological discussion in difficult cases.
- If the excision has been undertaken for calcification or for known DCIS, blocks should be taken to include areas of fibrous breast tissue proximal and distal to the calcification. DCIS, especially the low grade type, may be much more extensive than the radiologically apparent calcification.¹
- Blocks should be taken from the main area of calcification and also from proximal (towards the nipple) and distal to the calcification as DCIS extends most frequently in this plane.² Measurement can be made in this way from the most distal involved duct across the main area of calcification to the most proximal involved duct (see section 16.2).
- The number of blocks taken will depend on the size of the specimen and the size of the abnormality. If the specimen is small, it is often best to block and examine all of the tissue. Samples 30 mm or less in maximum dimension can be completely sliced, embedded and examined histologically.
- For larger specimens, sampling should include the extremes of the mammographic abnormality and adjacent tissue in order to avoid underestimation of the size of a lesion. This is particularly important as it is recognised that mammographic size may be an underestimate of true lesion size.
- If therapeutic samples are sent in more than one portion, it can be extremely difficult to measure the absolute largest extent of the whole lesion present. In these cases, it is appropriate to measure the maximum distance in any piece of tissue and to add the dimensions to give an estimated total size. If, however, the orientation of the specimens can be determined, the size can be ascertained more reliably.
- The margins of therapeutic excision specimens should also be sampled. The nearest margin to the mammographic abnormality must be blocked, as an absolute minimum, in order to facilitate measurement of this distance. Preferably, the margins should be more widely sampled to allow more accurate assessment of adequacy of excision. Examination of the margin closest to the nipple has also recently been shown to be valuable (T. Decker, personal communication).
- The use of different colour inks/markers on an individual section can assist microscopic identification of specific margins.

5.2 Method 2: serial slicing perpendicular to the superficial–deep plane (Figure 3)

- This is a variation of method 1 and is particularly suitable for smaller specimens in association with large block techniques. The entire specimen can be examined as a small number of serial large sections. The technique is similar to the method currently used to examine radical prostatectomy specimens in many centres.

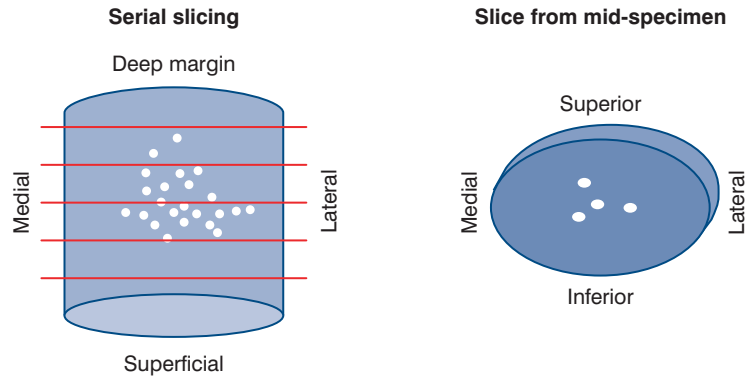


Figure 3 Method 2: serial slicing perpendicular to the superficial–deep plane.

5.3 Method 3: radial block examination, with or without shave margin (Figure 4)

- This method is the most commonly used for examination of a specimen containing a palpable or visible macroscopic abnormality. The lesion is sampled as a series of blocks, taken at right angles, as described below. Sampling of the margins is influenced by the surgical technique.

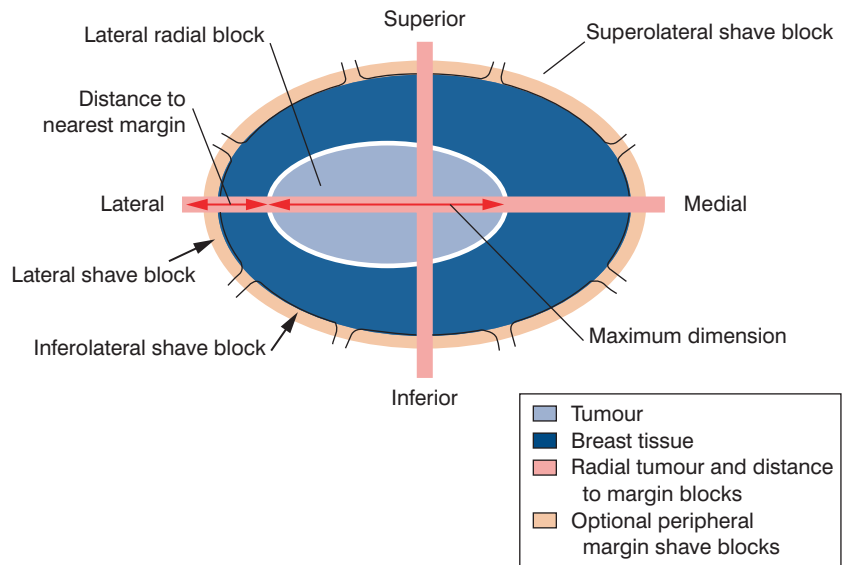


Figure 4 Method 3: radial block examination, with or without shave margin.

5.3.1 Tumour and margin sampling

- The specimen is usually incised from the posterior deep fascial plane in a cruciate fashion through the centre of the tumour. This allows the tumour to be sampled as four blocks, which include the anterior–posterior, medial–lateral and superior–inferior dimensions.

- It may be possible to take radial margin and the lesion in one block from smaller resections. Larger specimens may require tumour and margin blocking in two (or more) cassettes.
- Sections taken for measurement of distance to margins will include a slice through the lesion to the radial edges of the specimen and will allow measurement of the lesion to margin distance.
- One or more additional radial blocks extending to the closest margin (superolateral, superomedial, inferomedial, inferolateral) should be taken if these are the closest.
- For larger specimens, sampling should include the extremes of the mammographic abnormality and adjacent tissue in order to avoid underestimation of the size of a lesion. This is particularly important as it is recognised that mammographic size may be an underestimate of true lesion size.

5.3.2 *Cavity shave/biopsy specimens*

- The circumferential edge of the sample can be shaved to allow more extensive examination of relevant surgical resection margins. Alternatively, the surgeon may provide cavity shaves. This can produce a series of additional shave/cavity blocks: superior shave, superolateral shave, lateral shave, inferolateral shave, inferior shave, inferomedial shave, medial shave, and superomedial shaved edges, depending on the size of the specimen. The site of each specimen should be clearly labelled and each specimen examined separately.
- It should be noted that shaved edges of the margins of the specimen or examination of 'cavity shaves/bed biopsies' assess adequacy of excision but do not allow measurement of distance between tumour and margins.

6. RE-EXCISION SPECIMENS

- If the radiological abnormality extends close to a margin on the specimen radiograph, the surgeon may undertake an immediate re-excision of that particular margin.
- A separate re-excision specimen may therefore be taken (1) at the time of initial surgery, (2) subsequent to the discovery of incomplete excision in a therapeutic marker or (3) following diagnostic localisation biopsy.
- The aim is to remove either all of the previous biopsy site and its margins or one or more specific margins known, or suspected, to be involved by the disease process. Whenever re-excision has been performed, the surgeon should orientate the re-excision specimen. It is therefore possible to measure the distance of any additional tumour present to the new margin of excision, or to approximate the distance of the tumour to the new margin of excision if no tumour is present.
- If re-excision specimens have been taken which contain further tumour, it can be extremely difficult to determine the absolute size of lesion. A pragmatic approach is required, and the maximum distance in each piece of tissue can be measured and added to give an approximate total size of tumour. If, however, the orientation of the specimens can be determined, the size of tumour can be ascertained more reliably.

7. MASTECTOMY SPECIMENS

- Mastectomy specimens should be orientated by the surgeon, eg by placing a suture in the axillary tail. A diagram indicating the site of lesion (or lesions) may be helpful.
- A method should be employed to ensure rapid fixation of the tumour and the rest of the specimen. Ideally, this will be on receipt of the fresh specimen in the pathology laboratory, allowing immediate incision of the tumour and slicing of the breast prior to placing in fixative. If resources do not permit such a procedure, then alternatives must be employed, eg requesting that the surgeon routinely incises the specimen in a controlled way as described in Chapter 2. **Mastectomy specimens should not be allowed to fix intact without incision of the tumour.** Poor tumour preservation precludes assessment of minimum dataset details such as histological grade and vascular invasion and can result in false negative hormone receptor measurement.
- The specimen is conventionally incised from the posterior deep fascial plane in a cruciate fashion through the centre of the tumour. Alternatively, the whole specimen can be cut at approximately 1 cm intervals. The cruciate technique allows the tumour to be sampled as well fixed blocks, which include the anterior–posterior, medial–lateral and superior–inferior dimensions (Figure 5).
- The apparently normal portion of the mastectomy specimens should also be sliced at approximately 10 mm intervals and examined by eye and palpation to identify any additional abnormalities. These should be described and sampled.
- Additional representative sampling of the nipple–areolar complex can be performed to assess the presence of mammary Paget’s disease.
- Additional sampling of quadrants can be performed if resources permit as these can identify occult extensive disease.

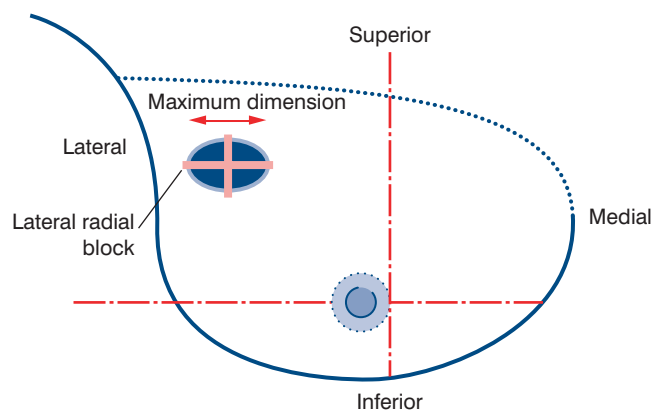


Figure 5 Mastectomy specimen.

8. PATHOLOGICAL EXAMINATION OF LYMPH NODES

8.1 Background

Resected lymph nodes, usually axillary and occasionally internal mammary, should be submitted for pathology examination for those patients undergoing surgery for invasive breast carcinoma. These specimens may take the form of axillary clearance specimens, lymph node samples or sentinel lymph node biopsies.

8.2 Lymph node sample specimens, including sentinel node samples

Specimen handling

- designated individual lymph node specimens should be identified separately from the breast sample and placed in clearly labelled specimen containers for routine fixation.

Tissue blocks

- each lymph node identified should be examined and blocked independently for histological examination
- the methodology used should provide the highest chance of finding metastatic disease by conventional microscopic examination of haematoxylin and eosin (H&E) stained tissue sections
- a representative complete section of any grossly involved lymph node is adequate
- lymph nodes greater than 5 mm in maximum size should be sliced at intervals of approximately 3 mm or less perpendicular to the long axis; this is an effective and simpler alternative to serial sectioning to detect small metastatic deposits in lymph nodes
- all of the tissue blocks prepared should be embedded and examined histologically; for larger lymph nodes, this may necessitate examination as more than one paraffin block
- lymph nodes less than 5 mm should, ideally, be bisected and blocked; alternatively, lymph nodes 5 mm or less can be blocked in their entirety
- examination of levels is not routinely necessary but may be performed if small groups of worrisome cells are identified, particularly if parenchymal in site.

8.3 Axillary clearance specimens

Pathological examination should be performed on all lymph nodes received, and the report should state the total number of lymph nodes and the total number containing metastasis.

Specimen handling

- axillary clearance specimens should be placed in clearly labelled containers for routine fixation.

Macroscopic examination

- axillary contents received with mastectomy or biopsy specimens should be examined carefully to maximise lymph node yield. This is usually achieved by manual dissection of fixed axillary tissue with careful examination by inspection and palpation. The yield of lymph nodes may be high in such samples. The use of clearing agents or Bouin's solution may increase lymph node

yield. However, this is time consuming and expensive and is not regarded as essential

- the axillary contents can be divided into three levels if the surgeon has marked the specimen appropriately. The apical lymph node should be separately identified, if identified surgically.

Tissue blocks

- a. Minimum standard method
 - every lymph node identified should be examined histologically
 - the method should ensure that the total number of lymph nodes should be assessable; this necessitates a minimum examination of at least one slice of tissue from each node
 - this minimum standard allows examination of multiple lymph nodes as composite blocks.
- b. Ideal methodology
 - the recommended methodology is as described above for lymph node sample specimens.

8.4 Sentinel lymph node biopsy samples

This is currently a research area and is being evaluated by large clinical trials. There is no clear evidence at present to justify additional studies, such as routine immunohistochemistry, being performed on such lymph nodes. The role of additional techniques is being examined in research centres.

8.5 Additional techniques for the examination of lymph nodes

Additional techniques for the assessment of lymph nodes for metastatic disease include sectioning at multiple levels, use of immunocytochemistry and molecular technology. These tests may increase the frequency of detection of micrometastatic disease, but at present the significance of such phenomena is uncertain. The significant additional resources required for such detailed lymph node examination cannot be justified as routine practice at present.

Should local interest or resources permit, the following could be considered (but is **not** part of routine practice):

- Immunocytochemical tests are an adjunct to conventional histology and can facilitate identification of micrometastatic disease through direct labelling of the tumour cell population, thus enhancing visualisation of small foci. They may be used for determination of cases where a few worrisome cells are seen on routine H&E stained sections. However, these isolated tumour cells are now generally believed to be of limited prognostic significance. Most research studies have used broad spectrum or low molecular weight cytokeratins such as MNF116, CAM5.2 or cytokeratin19. Reactivity of dendritic reticulum cells and some lymphoid cells may lead to false positive results when using some cytokeratin antibodies. Assessment must therefore be based on immunoreactivity and morphological correlation.

The frequency of detection of micrometastatic disease is also increased through examination of a greater proportion of the lymph node volume; methods can therefore aim to increase the area fraction of lymph nodes

examined. Methodology includes serial sectioning in some form. The majority of research studies to date have used three levels of serial sectioning at a separation of approximately 100 μm . Increasing the number of levels examined beyond this will increase detection but will reduce practicality and significantly increase costs. As noted earlier in this section, block preparation techniques can provide an effective alternative to serial sectioning to increase detection of small (<2 mm) metastatic deposits.

8.6 Frozen section examination

Frozen section examination of lymph nodes for metastatic carcinoma has a high risk of false negative (and also false positive) classification. For this reason, use of intraoperative frozen sections to examine axillary lymph nodes should be restricted to research trials and cannot be recommended for routine practice.

For reporting of lymph node specimens, see Chapter 19.

9. NHSBSP HISTOPATHOLOGY REPORTING FORM

The following chapters give guidance on how to use the NHSBSP histopathology reporting form (shown overleaf) and provide definitions for use on this form and the RCPATH breast cancer histopathology minimum dataset report (see Chapter 10). The wide bore needle biopsy form, which has also been amended, is included in Appendix 2.

The aim is not to replace standard textbooks of breast pathology but to focus on diagnostic criteria for including lesions in the various categories and therefore to help to achieve maximum uniformity of reporting. The guidance in this section is drawn mainly from texts of breast pathology and the experience gained in the UK External Quality Assurance Scheme in Breast Screening Histopathology.

It is not necessary to use the form as it appears in this document. It may be useful to undertake local modifications, particularly if the form is also to function as the definitive histopathology report that will be entered into the patient's notes and laboratory records. It is, of course, essential to record all the information requested by the form for submission to screening offices using the same terminology. Evaluation of the breast screening programme depends upon provision of accurate pathology data.

The use of synoptic reports is helpful as these may act as an aide-memoire for a complete dataset. An example format is given in Appendix 3. Alternatively, adaptations of the NHSBSP histopathology reporting form or the RCPATH minimum dataset report can be used.

Reporting forms can be obtained from, or may be generated in, breast screening offices. Copies of the forms can be downloaded from the NHS Cancer Screening Programmes website (www.cancerscreening.nhs.uk).

NHSBSP HISTOPATHOLOGY REPORTING FORM

Surname	Forenames	Date of birth
Screening number	Hospital number	NHS number
Pathologist	Laboratory	
Date of reporting	Report number	
Side	<input type="checkbox"/> Right <input type="checkbox"/> Left	

Specimen radiograph seen	<input type="checkbox"/> Yes	<input type="checkbox"/> No	
Mammographic abnormality present in specimen	<input type="checkbox"/> Yes	<input type="checkbox"/> No	<input type="checkbox"/> Unsure
Histological calcification	<input type="checkbox"/> Absent	<input type="checkbox"/> Benign	<input type="checkbox"/> Malignant <input type="checkbox"/> Both
Specimen type	<input type="checkbox"/> Localisation biopsy	<input type="checkbox"/> Open biopsy	
	<input type="checkbox"/> Wide local excision	<input type="checkbox"/> Segmental excision	
	<input type="checkbox"/> Mastectomy		
Specimen weight g		
Axillary procedure	<input type="checkbox"/> No lymph node procedure	<input type="checkbox"/> Sentinel node biopsy	
	<input type="checkbox"/> Axillary node sample	<input type="checkbox"/> Axillary node clearance	

Benign lesion present	<input type="checkbox"/> Yes <input type="checkbox"/> No	Malignant lesion present	<input type="checkbox"/> Yes <input type="checkbox"/> No
------------------------------	--	---------------------------------	--

Benign lesion

<input type="checkbox"/> Complex sclerosing lesion/radial scar	<input type="checkbox"/> Fibroadenoma	<input type="checkbox"/> Multiple papilloma
<input type="checkbox"/> Periductal mastitis/duct ectasia	<input type="checkbox"/> Fibrocystic change	<input type="checkbox"/> Solitary papilloma
<input type="checkbox"/> Sclerosing adenosis	<input type="checkbox"/> Solitary cyst	<input type="checkbox"/> Columnar cell change
<input type="checkbox"/> Other (please specify)		

Epithelial proliferation

<input type="checkbox"/> Not present	<input type="checkbox"/> Present without atypia
<input type="checkbox"/> Present with atypia (ductal)	<input type="checkbox"/> Present with atypia (lobular)

Malignant lesion

<i>In situ carcinoma</i>	<input type="checkbox"/> Not present			
<input type="checkbox"/> Ductal				
DCIS grade	<input type="checkbox"/> High	<input type="checkbox"/> Intermediate	<input type="checkbox"/> Low	<input type="checkbox"/> Not assessable
DCIS growth pattern(s)	<input type="checkbox"/> Solid	<input type="checkbox"/> Cribriform	<input type="checkbox"/> Micropapillary	<input type="checkbox"/> Papillary
	<input type="checkbox"/> Apocrine	<input type="checkbox"/> Flat	<input type="checkbox"/> Other (please specify)	
Size	mm (ductal only)			
<input type="checkbox"/> Lobular				
<input type="checkbox"/> Paget's disease				
Microinvasion	<input type="checkbox"/> Not present	<input type="checkbox"/> Present		

Invasive carcinoma Not present

Size Invasive tumour size mm (largest dimension of dominant invasive tumour focus)

Whole tumour size mm (invasive plus surrounding DCIS if DCIS extends > 1 mm beyond invasive)

Type No special type (ductal NST)

Pure special type (90% purity, specify components present below)

Mixed tumour type (50–90% special type component, specify components present below)

Other malignant tumour (please specify)

Specify type component(s) present for pure special type and mixed tumour types:

Tubular/cribriform Lobular Mucinous Medullary like Ductal/no special type

Other (please specify)

Invasive grade 1 2 3 Not assessable

Tumour extent Localised Multiple invasive foci

Vascular invasion Not seen Present Possible

Axillary nodes present: No Yes Total number Number positive

For single node positivity, specify Metastasis (> 2mm)

Micrometastasis (≤2mm to > 0.2mm)

Isolated tumour cells (≤0.2mm)

Other nodes present No Yes Total number Number positive

Site of other nodes

Excision margins (for DCIS or invasive carcinoma)

Not assessable Reaches relevant margin Does not reach relevant margin

Closest relevant margin mm

Oestrogen receptor status Positive Negative Quick (Allred) score

Not performed

Optional additional fields

Progesterone receptor status Positive Negative Quick (Allred) score

Not performed

HER 2 status Positive Negative Score

Not performed

Comments/additional information

Final histological diagnosis

Normal Benign Malignant

10. MINIMUM DATASET FOR BREAST CANCER HISTOPATHOLOGY

The minimum dataset for breast cancer histopathology was originally developed for The Royal College of Pathologists under the coordination of the late Professor JP Sloane, University of Liverpool. The reasons for defining a consistent dataset for reporting breast cancers include:

- the recognition that certain histopathological features of both in situ and invasive carcinoma are directly related to clinical outcome and may therefore be important in deciding the most appropriate treatment, including extent of surgery and use of and choice of adjuvant therapy
- using histopathological features to monitor breast screening programmes, the success of which is reflected by more favourable prognostic features of the cancers detected
- the identification by cancer registries of changing patterns of disease.

The minimum dataset has been revised to include oestrogen receptor status and classification of nodal metastasis. It should be applied for all breast cancers, ie both those that are screen detected and those presenting symptomatically.

The dataset has been approved by The Royal College of Pathologists, the NHSBSP, the European Commission Working Group for Breast Screening Pathology, the British Association of Surgical Oncologists, the British Breast Group and the United Kingdom Association of Cancer Registries.

BREAST CANCER HISTOPATHOLOGY MINIMUM DATASET REPORT

Surname _____ Forenames _____ Date of birth _____
 Sex _____ Hospital number _____ NHS number _____
 Date of reporting _____ Report number _____
 Side Right Left

Specimen type Localisation biopsy Open biopsy
 Wide local excision Segmental excision
 Mastectomy Wide bore needle biopsy

Specimen weight g

Axillary procedure No lymph node procedure Sentinel node biopsy
 Axillary node sample Axillary node clearance

In situ carcinoma Not present
 Ductal carcinoma in situ

DCIS grade High Intermediate Low Not assessable
 DCIS growth pattern(s) Solid Cribriform Micropapillary Papillary
 Apocrine Flat Other (please specify)

Size mm (DCIS only)
 Lobular carcinoma in situ
 Paget's disease

Microinvasion Not present Present

Invasive carcinoma Not present

Size
 Invasive tumour: mm (largest dimension of dominant invasive tumour focus)
 Whole size of tumour: mm (invasive plus surrounding DCIS if DCIS extends > 1 mm beyond invasive)

Type No special type (ductal NST)
 Pure special type (90% purity, specify components present below)
 Mixed tumour type (50–90% special type component, specify components present below)
 Other malignant tumour (please specify)

Specify type component(s) present for pure special type and mixed tumour types:

Tubular/cribriform Lobular Mucinous Medullary like Ductal/no special type
 Other (please specify)

Invasive grade 1 2 3 Not assessable
 Tumour extent Localised Multiple invasive foci
 Vascular invasion Not seen Present Possible

Axillary nodes present: No Yes Total number Number positive
 For single node positivity, specify Metastasis (> 2 mm)
 Micrometastasis (≤2 mm to > 0.2 mm)
 Isolated tumour cells (≤0.2 mm)

Other nodes present No Yes Total number Number positive
 Site of other nodes

Excision margins (for DCIS or invasive carcinoma)
 Not assessable Reaches relevant margin Does not reach relevant margin
 Closest relevant margin mm

Oestrogen receptor status Positive Negative Quick (Allred) score
 Not performed

11. RECORDING BASIC INFORMATION

- 11.1 Pathologist** The histopathologist must be registered at the breast screening office, otherwise his/her name will not be recognised by the computer.
- 11.2 Date** Refers to the date when the specimen was reported.
- 11.3 Side** Indicates left or right breast. For specimens from both sides, a separate form should be completed for each side.
- 11.4 Specimen radiograph seen?** Indicate whether you have seen a specimen radiograph.
- 11.5 Mammographic abnormality present in specimen?** Are you satisfied that the mammographic abnormality is present in the specimen? This may necessitate consultation with the radiologist responsible for examining the specimen radiograph. It is worth remembering that breast calcification may be due to calcium oxalate salts (weddelite), which can be detected optimally in histological sections using polarised light.
- 11.6 Histological calcification** Indicate whether calcification observed radiologically was seen on histological sections and, if so, whether it is present in benign or malignant changes or both.
- 11.7 Specimen type** Choose one of the following terms:
- Localisation biopsy: biopsy of impalpable lesion identified by radiological guided marking
 - Open biopsy: non-guided biopsy/excision including lumpectomy, tylectomy, dochectomy
 - Wide local excision
 - Segmental excision: includes wedge excisions, partial mastectomy and re-excision specimens for clearance of margins
 - Mastectomy
 - Wide bore needle biopsy: preoperative diagnostic needle biopsy.
- 11.8 Specimen weight** Record the weight of all biopsy and segmental excision specimens (except wide bore needle samples). Weight is more reproducible than three-dimensional measurement to determine volume, even taking into account the different densities of fat and fibrous tissue, which vary in proportion in breast specimens. Specimen weight is also used as the means of determining the likely cosmetic disadvantage to women undergoing benign biopsy in the NHSBSP.
- 11.9 Benign/malignant lesion present** Tick the appropriate 'yes' box if any benign or malignant lesion is present and 'no' if none is identified. Both benign and malignant boxes may be ticked as 'yes'.

12. CLASSIFYING BENIGN LESIONS

12.1 Complex sclerosing lesion/radial scar

The term complex sclerosing lesion/radial scar includes sclerosing lesions with a pseudoinfiltrative growth pattern. These have previously been given various names, including infiltrating epitheliosis, rosette like lesions, sclerosing papillary proliferation, complex compound heteromorphic lesions, benign sclerosing ductal proliferation, non-encapsulated sclerosing lesion, indurative mastopathy and proliferation centre of Aschoff.

The radial scar is generally 10 mm or less in diameter (Figure 6) and consists of a central fibroelastic zone from which radiate out tubular structures. These structures may be two layered or exhibit intraluminal proliferation. Tubules entrapped within the central zone of fibroelastosis exhibit a more random, non-organoid arrangement (Figure 7). Lesions greater than 10 mm are generally termed complex sclerosing lesions. They have all the features of radial scars and, in addition to their greater size, exhibit more disturbance of structure, often with nodular masses around the periphery. Changes such as papilloma formation, apocrine metaplasia and sclerosing adenosis may be superimposed on the main lesion. Some complex sclerosing lesions give the impression of being formed by coalescence of several adjacent sclerosing lesions. There is a degree of morphological overlap with some forms of ductal adenoma.

If the intraluminal proliferation exhibits atypia or amounts to in situ carcinoma, it should be recorded separately under the appropriate heading on the screening form.

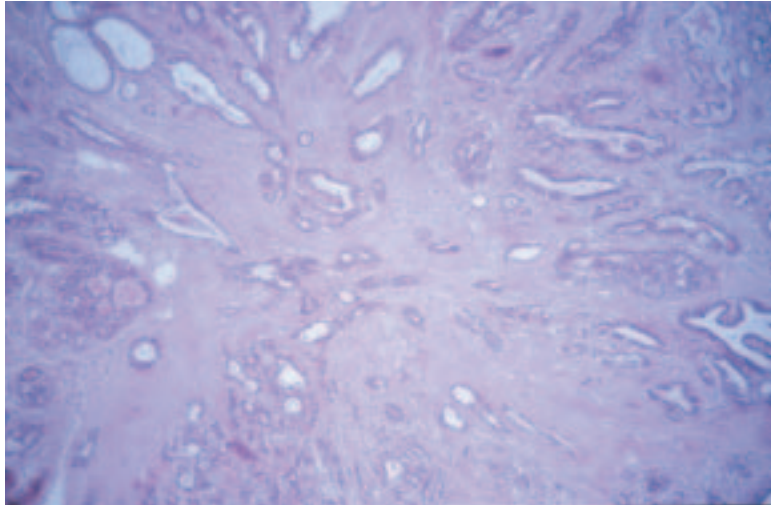
The main differential diagnosis is carcinoma of tubular or low grade 'ductal' type. The major distinguishing features are the presence of myoepithelium and basement membrane around the tubules of the sclerosing lesions. Immunocytochemical studies for basement membrane proteins and myoepithelial cells are useful. Cytological atypia is lacking, and any intratubular proliferation resembles hyperplasia of usual type unless atypical hyperplasia and/or in situ carcinoma are superimposed (see Chapter 13). Tubular carcinomas generally lack the characteristic architecture of sclerosing lesions.

12.2 Fibroadenoma

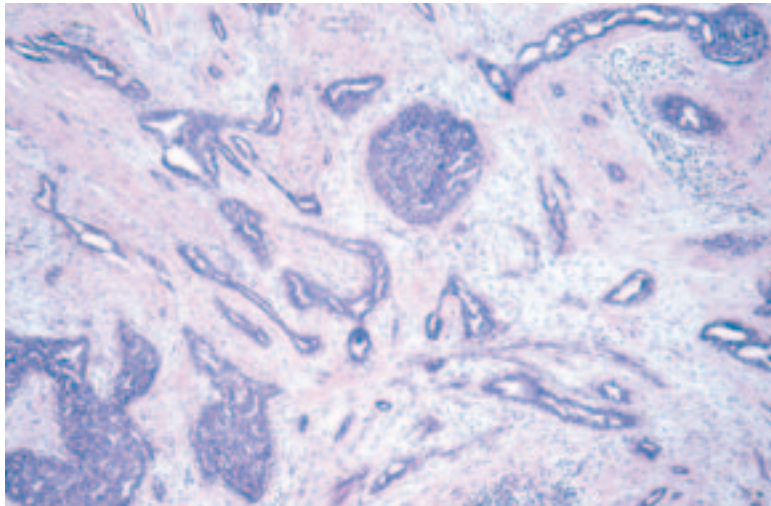
A benign lesion composed of connective tissue and epithelium exhibiting a pericanalicular and/or intracanalicular growth pattern (Figures 8 and 9). The connective tissue is generally composed of spindle cells, but may rarely also contain other mesenchymal elements such as fat, smooth muscle, osteoid or bone. Myxoid change may be marked. The epithelium is usually double layered, but some changes commonly seen in the epithelium elsewhere in the breast (eg apocrine metaplasia, sclerosing adenosis, blunt duct adenosis, hyperplasia of usual type) may occur in fibroadenomas. These do not need to be recorded separately unless they amount to atypical hyperplasia or in situ carcinoma.

Sometimes individual lobules may exhibit increased stroma, producing a fibroadenomatous appearance; occasionally, such lobules may be loosely

(a)



(b)



(c)

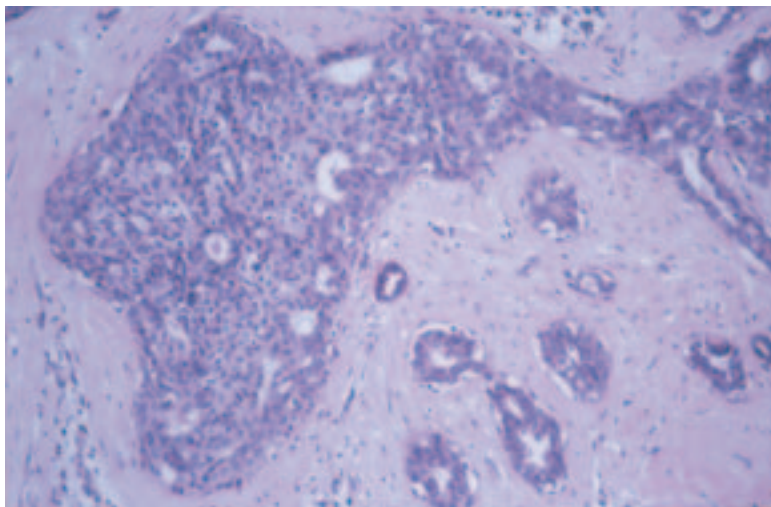


Figure 6 A radial scar showing the typical stellate appearance with central elastosis (a) and trapped tubules (b). There may be associated epithelial hyperplasia (c).

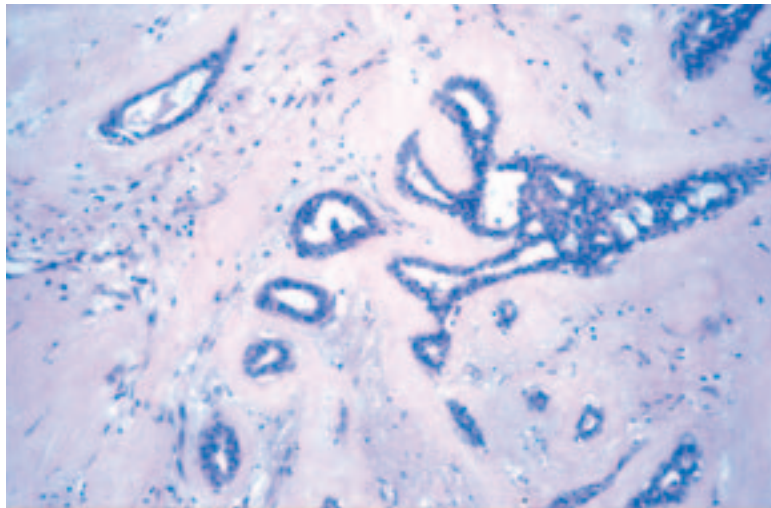


Figure 7 Trapped tubules in a radial scar usually have random placement.

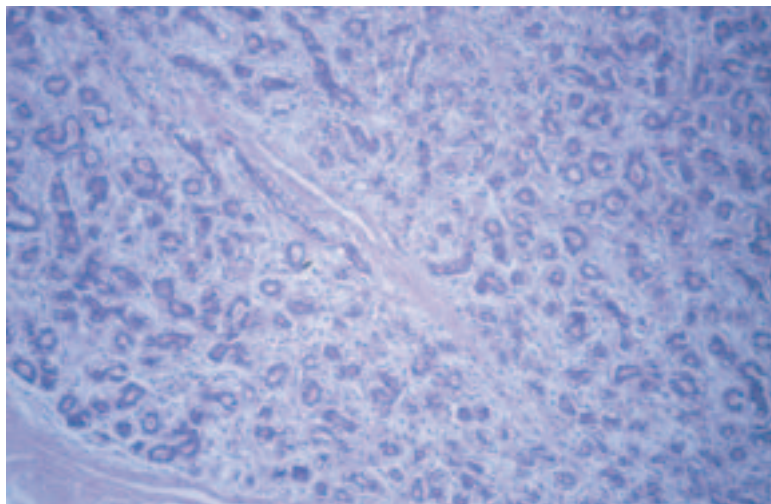


Figure 8 An example of pericanalicular fibroadenoma.

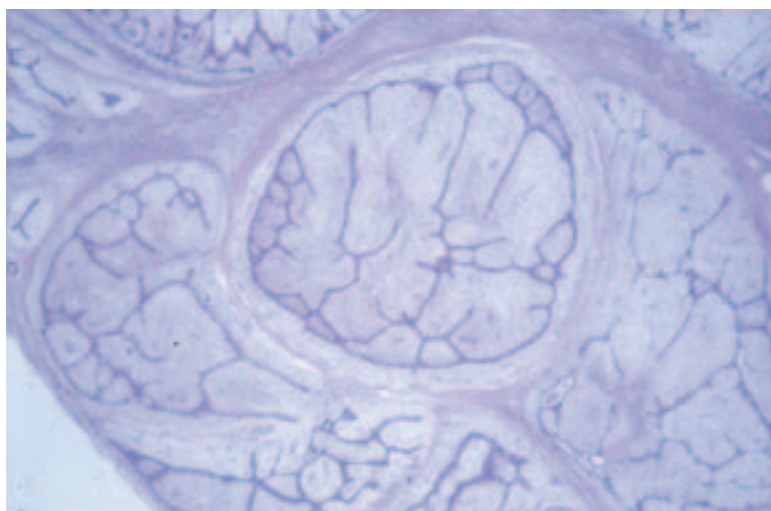


Figure 9 An example of intracanalicular fibroadenoma.

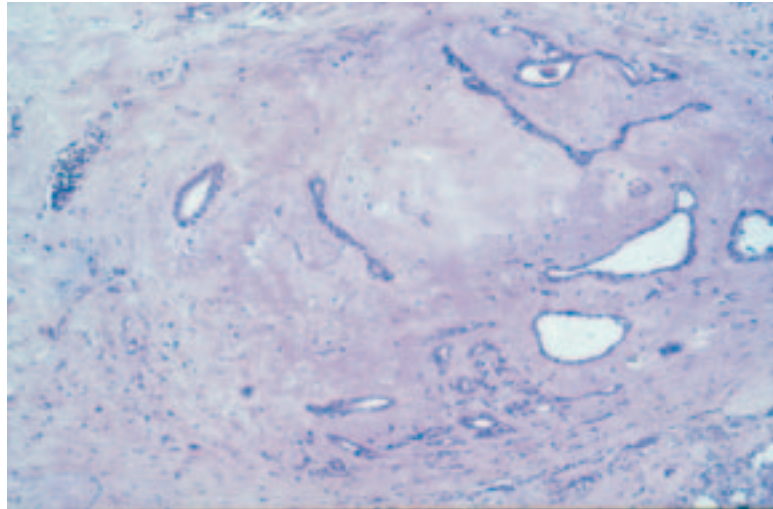


Figure 10 Fibroadenomatoid hyperplasia is a microfolcal lobular proliferation resembling a microscopic fibroadenoma.

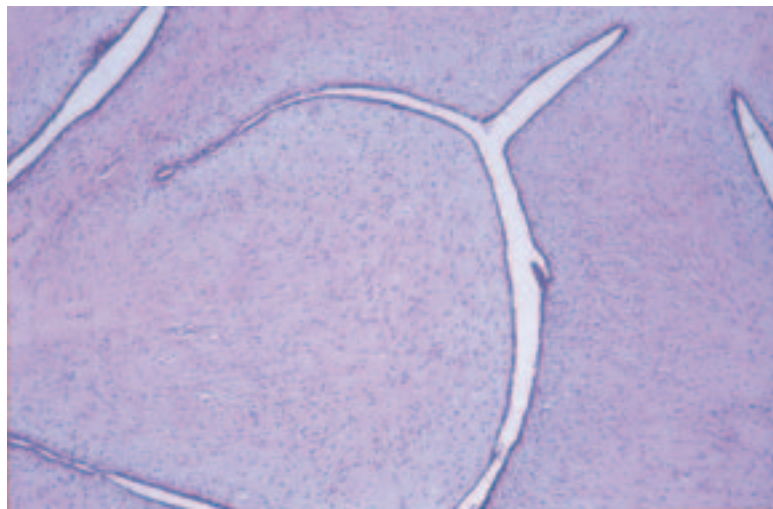


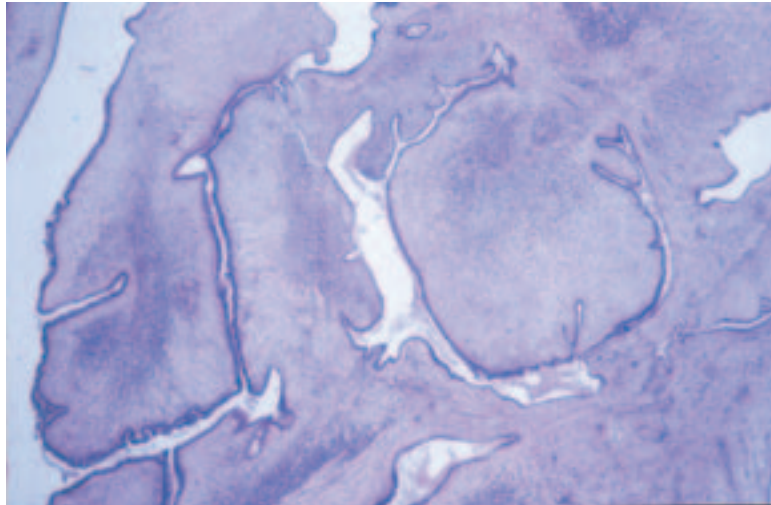
Figure 11 An example of a benign phyllodes tumour with the typical leaf like architecture.

coalescent (Figure 10). These changes are often called fibroadenomatoid hyperplasia or sclerosing lobular hyperplasia, but may be recorded as fibroadenoma on the reporting form if they produce a macroscopically visible or palpable mass. Consequently, fibroadenomas need not be perfectly circumscribed.

Old lesions may show hyalinisation and calcification (and less frequently ossification) of stroma and atrophy of epithelium. Fibroadenomas are occasionally multiple. For the purposes of the screening form, tubular adenomas can be grouped under fibroadenomas. Malignant change occurs rarely in the epithelial component. This is more frequently lobular carcinoma in situ than ductal carcinoma in situ (DCIS).

Fibroadenomas should be distinguished from **phyllodes tumours** (Figure 11). The high grade or 'malignant' phyllodes tumours are easily identified by their sarcomatous stroma (Figure 12). The low grade variants are more difficult to distinguish, but the main feature is the more cellular stroma.

(a)



(b)

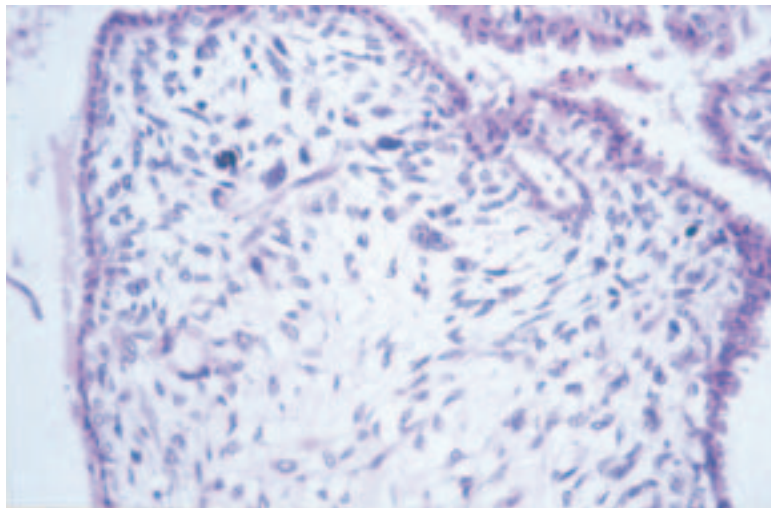


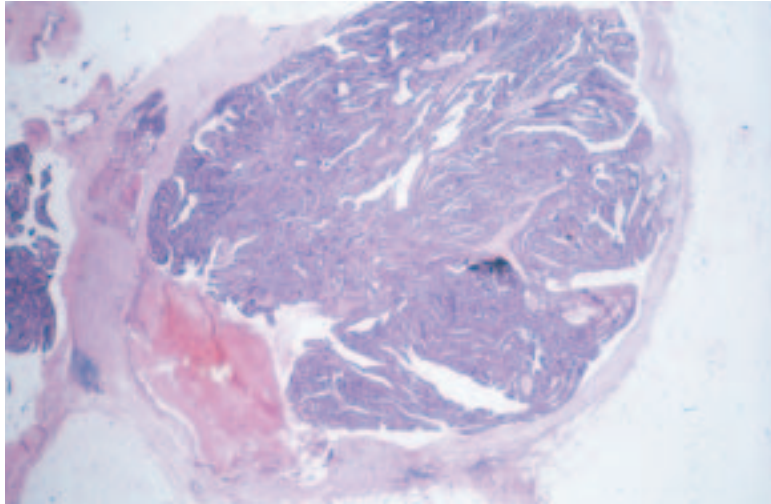
Figure 12 (a and b) An example of a malignant phyllodes tumour with focal marked increased stromal cellularity and pleomorphism and high mitotic frequency.

In younger women, however, the stroma in a fibroadenoma may be more cellular. Phyllodes tumours may also exhibit an enhanced intracanalicular growth pattern with club-like projections into cystic spaces, and there is often overgrowth of stroma at the expense of the epithelium. Adequate sampling is important as the characteristic stromal features may be seen only in parts of the lesion. Although phyllodes tumours are generally larger than fibroadenomas, size is not an acceptable criterion for diagnosis; fibroadenomas may be very large and phyllodes tumours small. For purposes of convenience, benign and borderline phyllodes tumours should be specified under ‘other benign lesions’ and malignant phyllodes tumours under ‘other malignant lesion’, although it is recognised that histological appearance is often not a good predictor of behaviour.

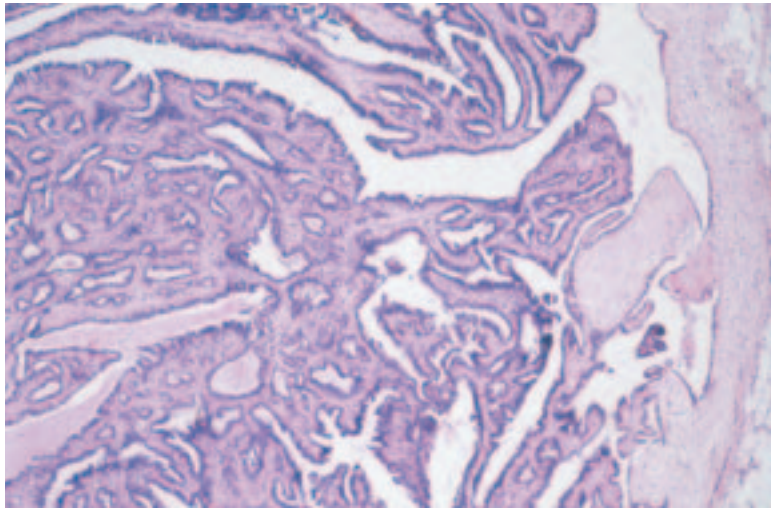
12.3 Papilloma

A papilloma is defined as a tumour with an arborescent, fibrovascular stroma covered by epithelium generally arranged in an inner myoepithelial and outer epithelial layer (Figure 13). Epithelial hyperplasia without cytological atypia is often present and should not be recorded separately.

(a)



(b)



(c)

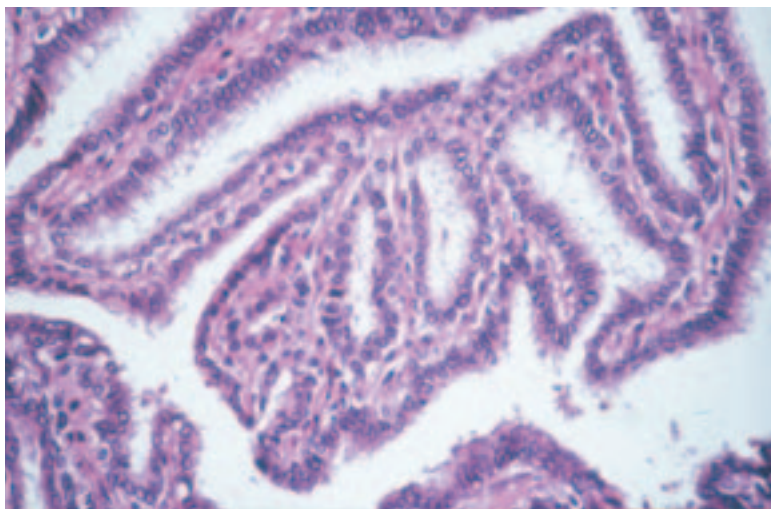


Figure 13 A papilloma with a fronded structure (a and b). The fibrovascular fronds are covered by a bilayer of myoepithelial and epithelial cells (c).

Atypical hyperplasia is rarely seen and, when present, should be recorded separately under ‘Epithelial proliferation’. Epithelial nuclei are usually vesicular with delicate nuclear membranes and inconspicuous nucleoli. Apocrine metaplasia is frequently observed, but should not be recorded separately on the reporting form. Squamous metaplasia is sometimes seen, particularly near areas of infarction. Sclerosis and haemorrhage are not uncommon and, where the former involves the periphery of the lesion, may give rise to epithelial entrapment with the false impression of invasion. The benign cytological features of such areas should enable the correct diagnosis to be made.

The term ‘**intracystic papilloma**’ is sometimes used to describe a papilloma in a widely dilated duct. These tumours should simply be classified as papilloma on the form. To distinguish these tumours from **encysted papillary carcinoma**, see Table 1 and section 14.1.2.

Papillomas may be **solitary** or **multiple**. The former usually occurs centrally in subareolar ducts, whereas the latter are more likely to be peripheral and involve terminal duct lobular units. The distinction is important as the multiple form is more frequently associated with atypical hyperplasia and DCIS, the latter usually of low grade type, which should be recorded separately. This malignant change may be focal within the

Table 1 Distinction of papilloma from encysted papillary carcinoma

Histological features	Papilloma	Encysted papillary carcinoma
1. Fibrovascular cores	Usually broad and extend throughout the lesion	Very variable, usually fine and may be lacking in at least part of the lesion
2. Cells covering papillae		
a. Basal	Myoepithelial layer always present	Myoepithelial cells usually absent, but when present may form a discontinuous layer
b. Luminal	Single layer of regular luminal epithelium OR features of regular usual type hyperplasia	Cells often taller and more monotonous with oval nuclei, the long axes of which lie perpendicular to the stromal core of the papillae. Nuclei may be hyperchromatic. Epithelial multilayering frequent, often producing cribriform and micropapillary patterns of DCIS overlying the papillae or lining the cyst wall
3. Mitoses	Infrequent with no abnormal forms	More frequent; abnormal forms may be seen
4. Apocrine metaplasia	Common	Rare
5. Surrounding tissue	Benign changes may be present including regular epithelial hyperplasia	Surrounding ducts may show DCIS
6. Necrosis and haemorrhage	May occur in either. Not a useful discriminating feature	
7. Periductal and intratumoral fibrosis	May occur in either. Not a useful discriminating feature	

NB All the features of a lesion should be taken into account when making a diagnosis. No criterion is reliable alone.

lesion, and therefore extensive sampling may be required to detect it. Some subareolar papillomas causing nipple discharge may be very small, and extensive sampling may be required to detect them.

Lesions termed **ductal adenoma** exhibit a variable appearance (Figure 14), which overlaps with other benign breast lesions. They may resemble papillomas except that they exhibit an adenomatous rather than a papillary growth pattern. These cases should be grouped under papilloma on the form. Indeed, some tumours may exhibit papillary and adenomatous features. Some ductal adenomas may show pronounced central and/or peripheral fibrosis and overlap with complex sclerosing lesions (see section 12.2).

The condition of **adenoma of the nipple** (subareolar duct papillomatosis) (Figure 15) should not be classified as papilloma in the screening form but specified under 'Other benign lesions'. This should be distinguished from the rare syringomatous adenoma of the nipple composed of ducts and tubules with an apparent infiltrative pattern.

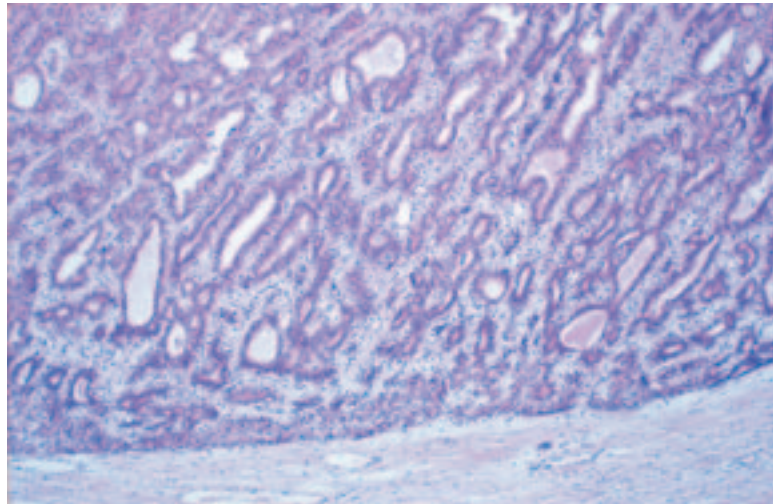


Figure 14 An example of a ductal adenoma.

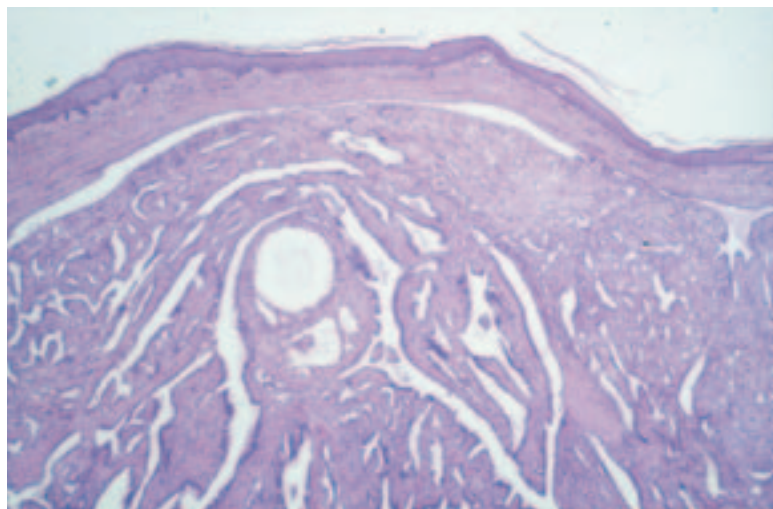


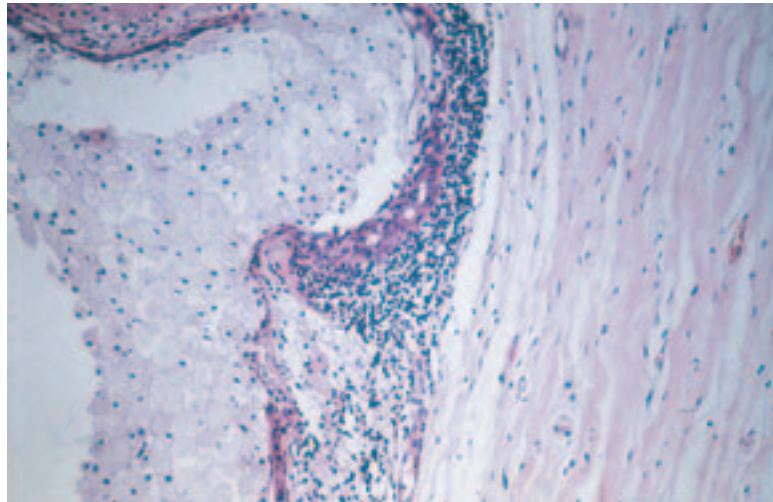
Figure 15 An example of an adenoma of nipple showing florid glandular proliferation.

Diffuse microscopic papillary hyperplasia should be recorded under 'Epithelial proliferation' in the appropriate box, depending on whether atypia is present or not.

12.4 Periductal mastitis/ duct ectasia (plasma cell mastitis)

This process involves larger and intermediate size ducts, generally in subareolar location. The ducts are lined by normal or attenuated epithelium, are filled with amorphous, eosinophilic material and/or foam cells, and exhibit marked periductal chronic inflammation, often with large numbers of plasma cells (periductal mastitis) (Figure 16). There may be pronounced periductal fibrosis. The inflammatory infiltrate may contain large numbers of histiocytes, giving a granulomatous appearance. Calcification may be present. The process may ultimately lead to obliteration of ducts, leaving dense fibrous masses. Persistence of small tubules of epithelium around the periphery of an obliterated duct results in a characteristic garland pattern. Duct ectasia is often associated with nipple discharge or retraction.

(a)



(b)

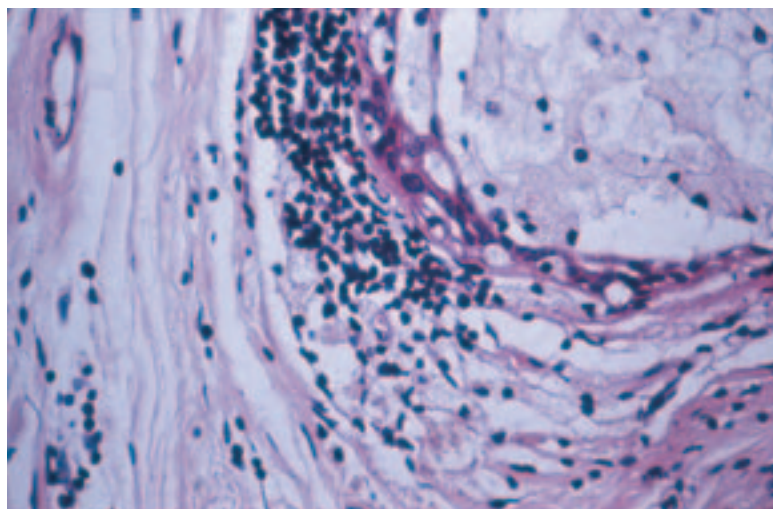


Figure 16 (a and b) An example of periductal mastitis showing periductal chronic inflammation with foamy macrophages in the luminal space.

Cysts are distinguished from duct ectasia by their rounded rather than elongated shape, tendency to cluster, lack of stromal elastin, frequent presence of apocrine metaplasia and less frequent presence of eosinophilic material or foam cells in the lumina.

12.5 Fibrocystic change

This term is used for cases with several to numerous macroscopically visible cysts, the majority of which are usually lined by apocrine epithelium (Figure 17). The term is not intended for use with minimal alterations such as fibrosis, microscopic dilatation of acini or ducts, lobular involution, adenosis and minor degrees of blunt duct adenosis. These changes should be indexed as normal.

It is not intended that cystic change or apocrine metaplasia (Figure 18) occurring within other lesions such as fibroadenomata, papillomata or sclerosing lesions should be coded here.

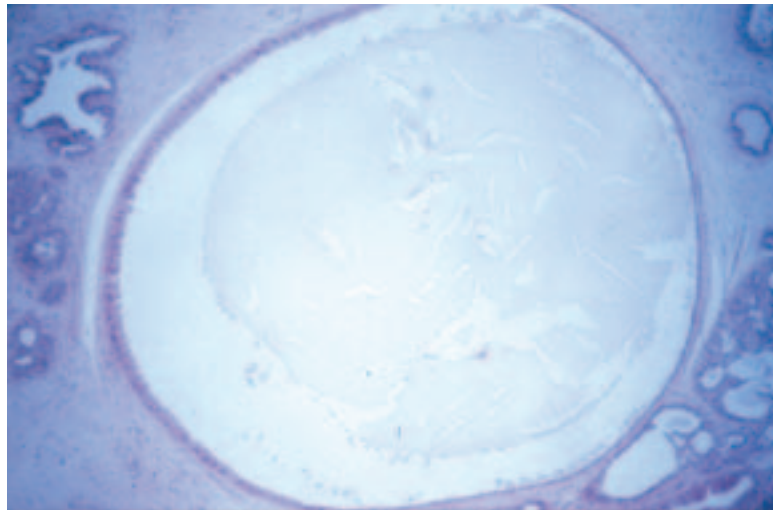


Figure 17 An example of fibrocystic change.

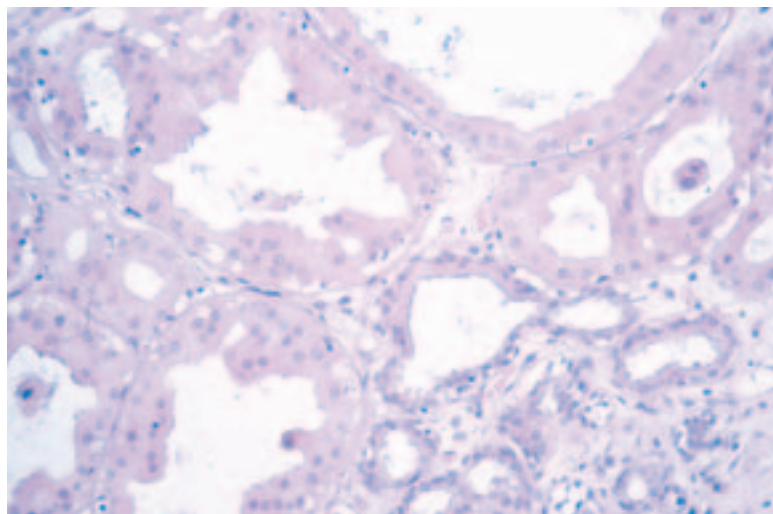


Figure 18 An example of apocrine metaplasia arising in an area of fibrocystic change.

Apocrine metaplasia occurring in lobules without cystic change may produce a worrisome appearance, occasionally mistaken for carcinoma. This change should be specified as 'Apocrine adenosis' under 'Other benign lesions'.

Papillary apocrine hyperplasia (Figure 19) should be indexed separately under epithelial proliferation with or without atypia, depending on its appearance. Apocrine metaplasia lining cysts is classified into simple, complex (with small papillae) and highly complex (with interconnecting bars and bridges). It should be noted that apocrine cells often exhibit a degree of pleomorphism greater than is seen in normal breast cells. Hyperplasia should therefore be regarded as atypical only when the cytological changes are significantly more pronounced than usual with a greater than threefold variation in nuclear size.

12.6 Sclerosing adenosis

Sclerosing adenosis is an organoid lobular enlargement in which increased numbers of acinar structures exhibit elongation and distortion (Figure 20). The normal two-cell lining is retained, but there is myoepithelial and stromal hyperplasia. The acinar structures may infiltrate adjacent connective tissue and occasionally nerves and blood vessels, which can lead to an erroneous diagnosis of malignancy. Early lesions of sclerosing adenosis are more cellular, and later ones more sclerotic. Calcification may be present.

There may be coalescence of adjacent lobules of sclerosing adenosis to form a mass detectable by mammography or macroscopic examination. The term 'nodular sclerosing adenosis' has been used to describe such lesions. It is recommended that sclerosing adenosis is not entered on the screening form if it is a minor change detectable only on histological examination. Although sclerosing adenosis often accompanies fibrocystic change (see section 12.5), this is not always the case and the two changes should be recorded separately.

Occasionally, apocrine metaplasia is seen in areas of sclerosing adenosis (apocrine adenosis) (Figure 21). It can produce a worrying appearance

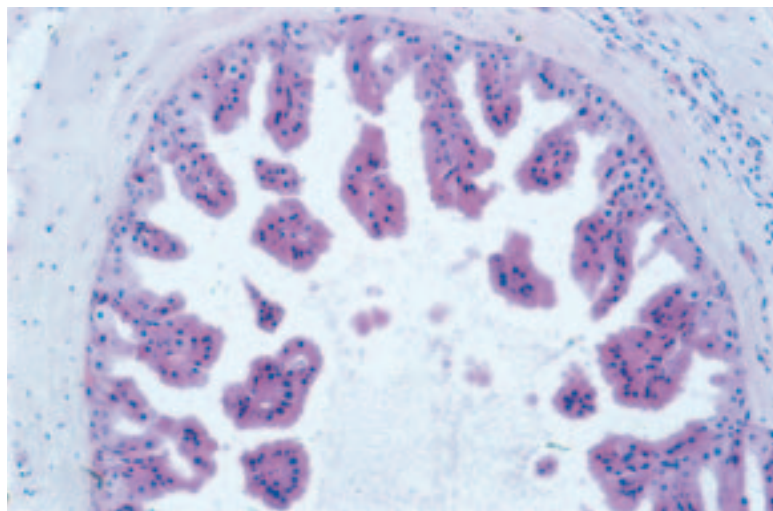


Figure 19 An example of papillary apocrine change.

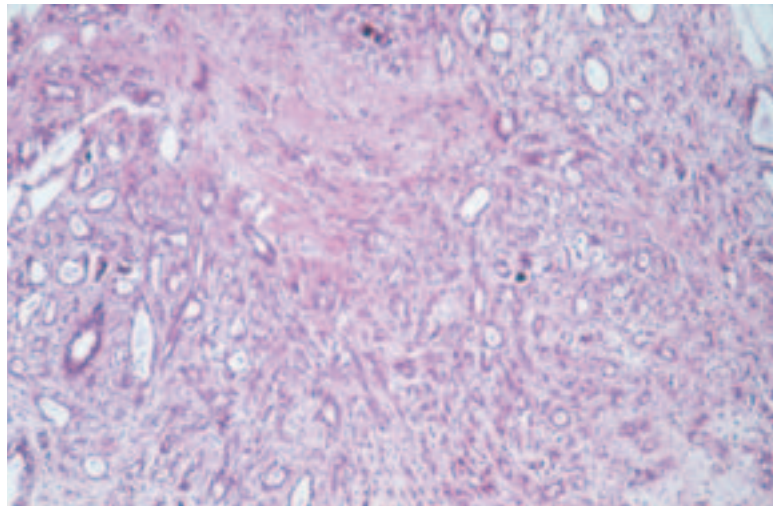


Figure 20 An example of sclerosing adenosis with the typical organoid lobular proliferation, including luminal epithelial lined glands and myoepithelial and stromal cells.

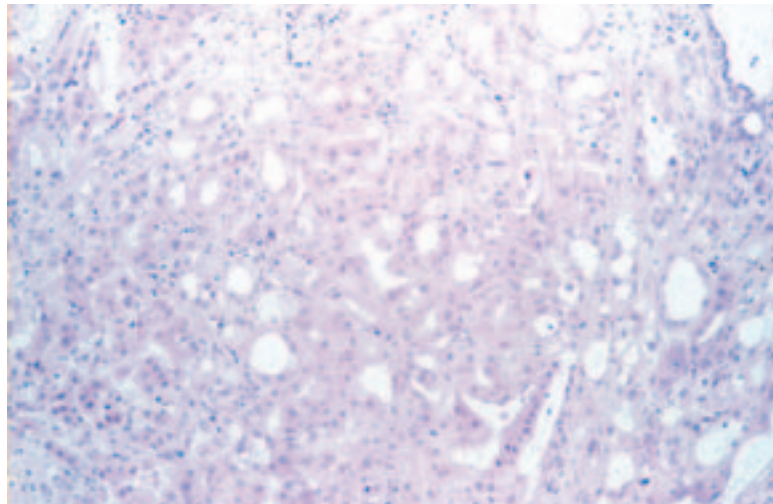


Figure 21 Apocrine adenosis.

and should not be mistaken for malignancy. This has a low power lobular architecture and there are usually adjacent benign changes with sclerosing adenosis and apocrine metaplasia.

Rarely, the epithelium in sclerosing adenosis may show atypical hyperplasia or in situ carcinoma. In such cases, these changes should be recorded separately on the reporting form.

The differential diagnosis of sclerosing adenosis includes tubular carcinoma, microglandular adenosis and radial scar. In tubular carcinoma, the infiltrating tubules exhibit cytological atypia and lack basement membrane, myoepithelium and lobular organoid growth pattern: ductal carcinoma in situ is a frequent accompaniment. Microglandular adenosis differs from sclerosing adenosis in lacking the lobular organoid growth pattern and is composed of rounded tubules lined by a single layer of cells lacking cytological atypia. The glandular distortion of sclerosing

adenosis is lacking. Radial scar is distinguished from sclerosing adenosis by its characteristic floret type growth pattern with ductolobular structures radiating out from a central zone of dense fibroelastotic tissue. Furthermore, the compression of tubular structures associated with myoepithelial and stromal hyperplasia is lacking. Immunocytochemical studies using antibodies to collagen IV or laminin and smooth muscle actin may be very useful.

12.7 Solitary cyst

This term should be used when the abnormality appears to be a solitary cyst (Figure 22). The size is usually greater than 10mm and the lining is attenuated or apocrine in type. The latter may show papillary change, which should be indexed separately under epithelial proliferation of appropriate type. If multiple cysts are present, it is better to use the term 'fibrocystic change' as above. Intracystic papillomas and intracystic papillary carcinomas should not be entered here but under 'Papilloma' or 'Carcinoma'.

12.8 Columnar cell change

A spectrum of changes ranging from bland columnar cell change to columnar cell hyperplasia with atypia is increasingly recognised as a result of extensive investigation of radiological calcification (Figure 23).

At present, there is no internationally accepted classification or terminology for this range of lesion. Synonyms are: blunt duct adenosis, columnar cell change, columnar cell hyperplasia, unfolded lobule, CAPSS, columnar cell atypia). In this edition, we would endorse the recent overview summary of available data and outline classification proposed by Schnitt.⁵

In columnar cell change, lobules are expanded and lined by epithelial cells with a columnar morphology. Other features include increased cytoplasm and apical snouts. The associated luminal secretions often undergo calcification. A single layer of columnar epithelial cells is the norm, although minor multilayering and tufting may be present. If greater degrees of multilayering of the epithelial cells is seen, the process is clas-

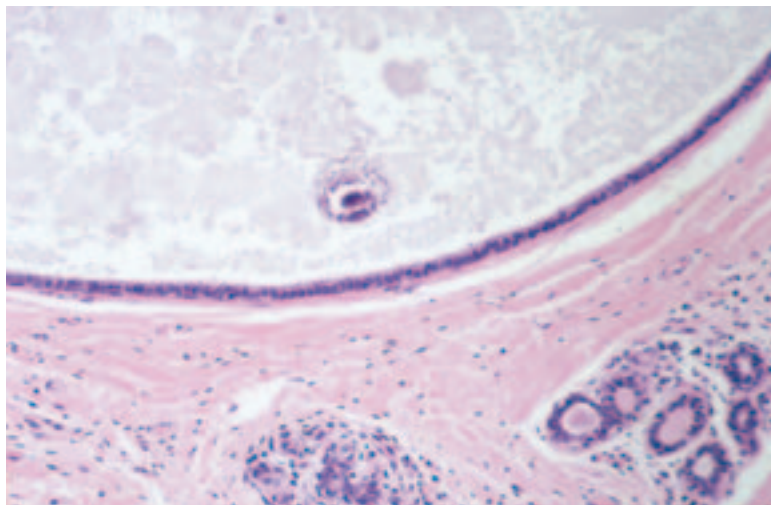


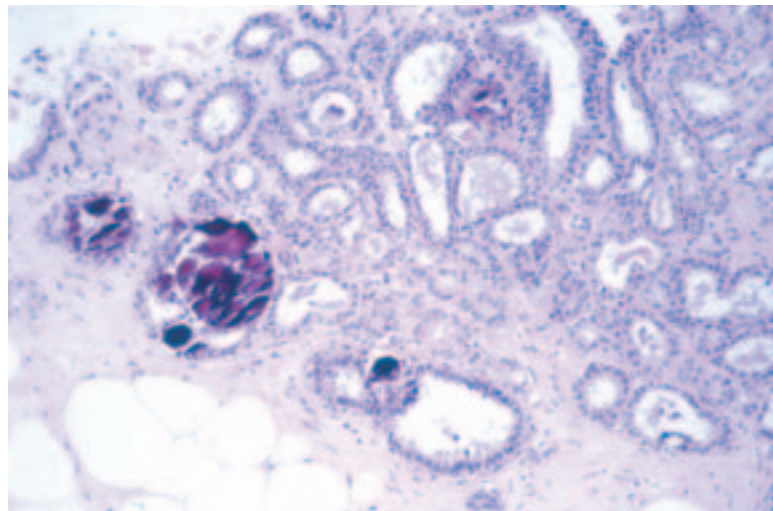
Figure 22 A cyst showing calcification of the fluid contents.

sified as columnar cell hyperplasia. At present, this is considered to be equivalent to usual epithelial hyperplasia. True micropapillary structures lacking fibrovascular cores and epithelial bridges are not seen in this form. If such architectural atypia, usually in the form of bulbous micropapillary structures, is identified, the lesion is categorised as columnar cell hyperplasia with architectural atypia. This process is described in section 13.2.1.

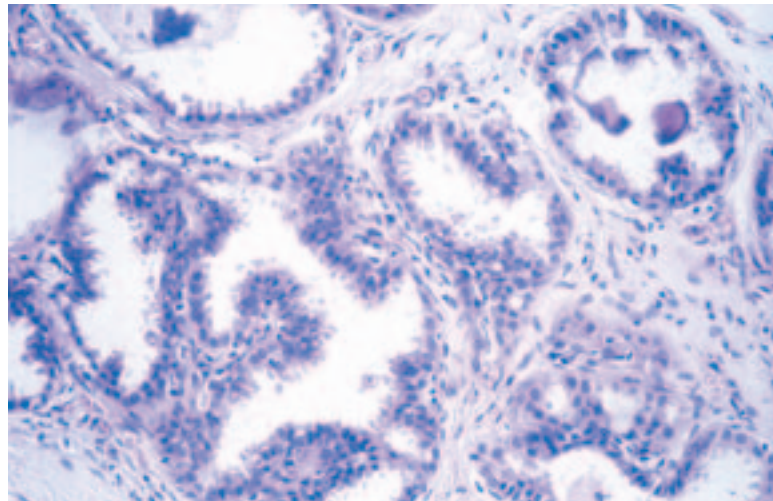
If superimposed cytological atypia is seen, the lesion is classified as columnar cell hyperplasia with atypia. Less commonly, columnar cell change without hyperplasia shows cytological atypia of a degree to cause concern but not amounting to flat in situ carcinoma. The epithelial cells are usually single layered and show mild to moderate degrees of cytonuclear atypia with clumped chromatin or vesicular nuclei or prominent multiple nucleoli.

Figure 23 (a–d) Columnar cell alteration is being more frequently identified in the mammographic screening programme because of its association with microcalcification. It may exhibit epithelial hyperplasia and architectural growth pattern atypicalities as well as cytonuclear atypia merging into the spectrum of DCIS and atypical ductal hyperplasia (d).

(a)



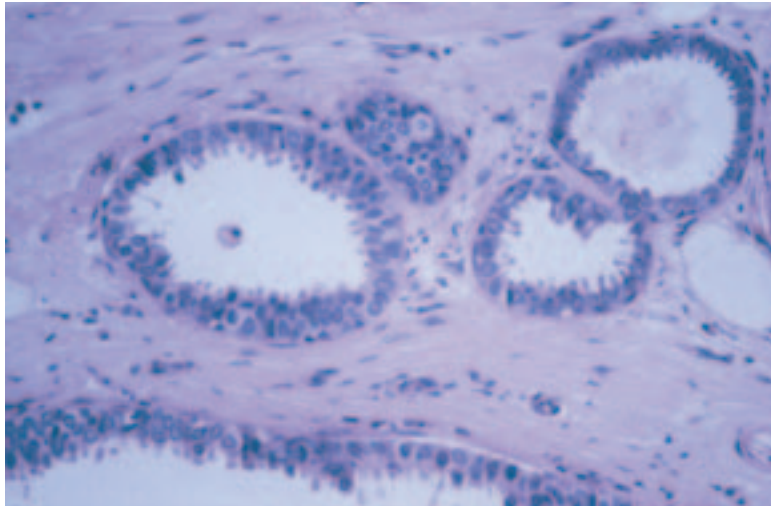
(b)



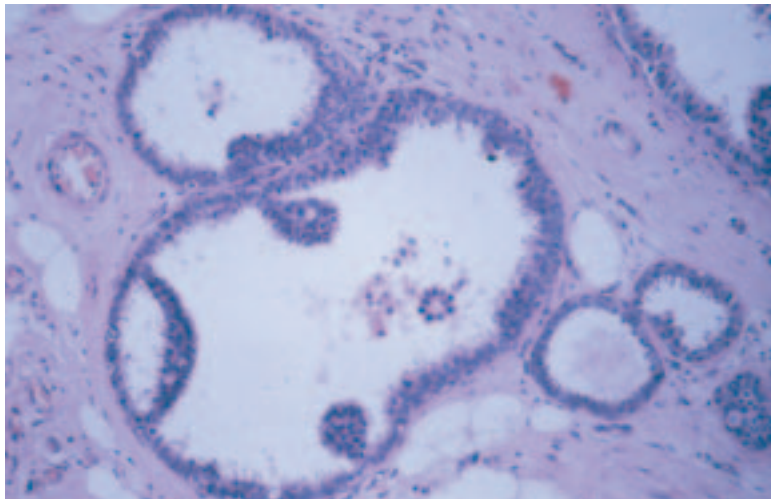
Columnar cell alterations and hyperplasia should be classified as a variant of fibrocystic change, and should be recorded on the NHSBSP breast pathology data form as columnar cell change. Neither columnar cell hyperplasia with atypia nor columnar cell atypia in isolation show features that fulfil the criteria for classic atypical ductal hyperplasia (ADH)⁴ (see section 13.3) and should also be classified as fibrocystic change. However, other epithelial proliferations may merge or be associated with columnar cell hyperplasia, including atypical ductal hyperplasia, conventional forms of DCIS (usually of low grade micropapillary or cribriform type), lobular carcinoma in situ (LCIS) and invasive carcinoma of low grade tubular or tubulolobular type.⁶ The presence of such associations should be recorded as fibrocystic change plus the additional type or type of lesion.

Figure 23 (a–d) Continued.

(c)



(d)



12.8.1 Proposed categorisation of columnar cell lesions

- Columnar cell change
- Columnar cell hyperplasia
- Columnar cell hyperplasia with architectural and/or cytological atypia
- Columnar cell change with cytological atypia
- Flat in situ carcinoma.

It should be noted that the columnar cell epithelial cell proliferation may show homogeneous oestrogen receptor positivity and similarly does not show the heterogeneity of cytokeratin expression of classic usual epithelial hyperplasia, as described in section 13.2 and Table 2. These data support the emerging view that these lesions are a low grade form of breast epithelial neoplasia.

12.8.2 Recording columnar cell alterations

At present, these lesions should be recorded on the breast screening form according to their broad category:

- benign columnar alterations without atypia, or with minor degrees of atypia, as ‘columnar cell change’
- columnar cell change with significant atypia as ‘present with atypia (ductal)’ (see section 13.3)
- lesions fulfilling the criteria for DCIS as such.

12.9 Other (specify)

This category is intended for use with less common conditions that form acceptable entities but cannot be entered into the categories above, eg fat necrosis, lipoma, adenoma of nipple, benign and borderline phyllodes tumours. Mammary duct fistula (recurring subareolar abscess) should be coded under ‘Other benign lesions’. The index in Appendix 4 should help as a reference for lesions difficult to place in any of the above categories. The computer system will not accept an entry under this heading unless a specific diagnosis is given.

13. CLASSIFYING EPITHELIAL PROLIFERATION

This section is for recording intraluminal epithelial proliferation in terminal duct lobular units or interlobular ducts.

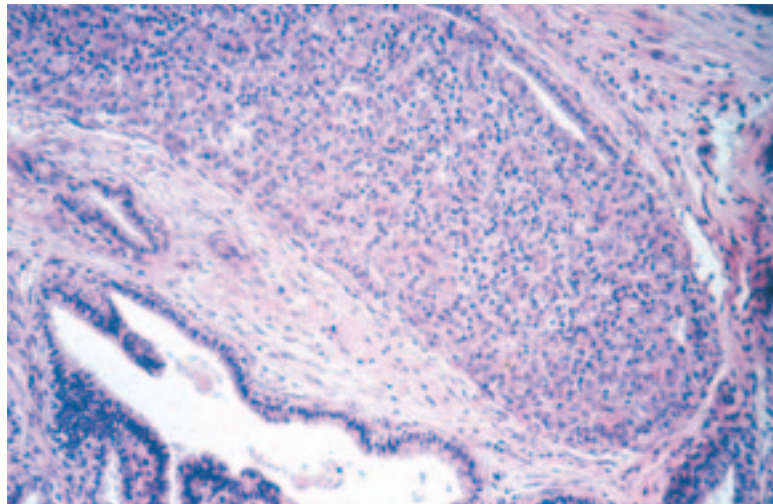
13.1 Not present

This should be ticked if there is no epithelial multilayering (apart from that ascribed to cross-cutting).

13.2 Present without atypia

This term should be used to describe all cases of intraluminal proliferation showing no or only mild atypia. The proliferation may vary from mild usual epithelial hyperplasia (up to four cell layers thick) to florid hyperplasia (Figure 24). The changes may involve terminal duct lobular units or interlobular ducts.

(a)



(b)

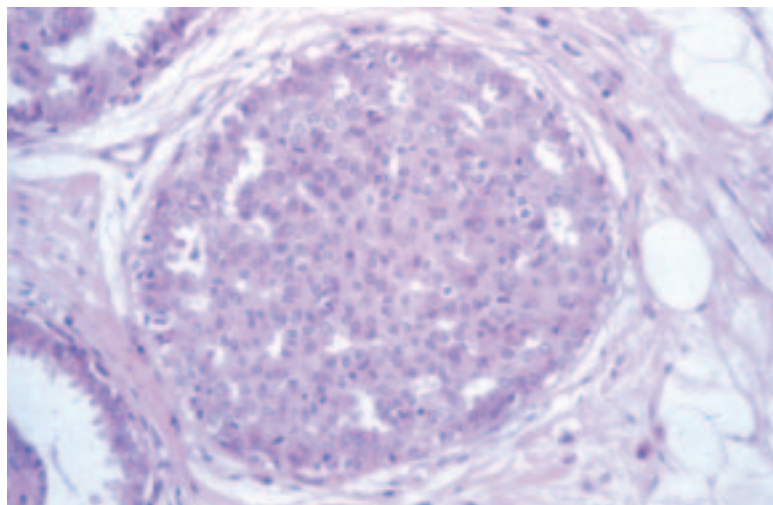


Figure 24 (a and b) Two examples of usual epithelial hyperplasia showing a haphazardly arranged mixed population of cells filling a duct space. The secondary luminal spaces are angulated and frequently peripherally placed.

The major features are:

- a mixed cell population comprising epithelial cells, basal/myoepithelial cells and metaplastic apocrine cells
- immunoreactivity for luminal epithelial cytokeratins (CK8, 18, 19) and basal epithelial cytokeratins (CK5, 6, 14) may be helpful in identifying a mixed cell population in usual epithelial hyperplasia;³ it should be noted, however, that cells of basal intermediate type are absent in columnar and apocrine proliferations
- indistinct cell margins leading to a syncytial growth pattern
- irregular and slit like lumina
- peripheral lumina
- streaming epithelial bridges
- infrequent mitoses with no abnormal forms.

The distinctions from atypical ductal hyperplasia and low grade DCIS are summarised in Figure 25 and Table 2.

13.2.1 Hyperplasia with cytological atypia (not atypical ductal hyperplasia of Page and Rogers type)

Some hyperplastic lesions exhibit characteristics and degrees of cytological atypia that do not fit into the category of atypical ductal hyperplasia (ADH) as described by Page and Rogers (see section 13.3.1). These have been increasingly seen in biopsies carried out for mammographic microcalcification. Various terms have been used, including columnar cell atypia, hypersecretory hyperplasia (with and without atypia), atypical cystic lobules, unfolded lobules and columnar alteration with prominent apical snouts and secretions (CAPSS).⁴ Currently, the biological significance of these lesions is unclear. They are, however, worthy of recording as they are increasingly being identified, particularly in biopsies carried out for microcalcification seen on mammography. The majority of these lesions fall into the broad category of columnar cell alterations (see section 12.8).

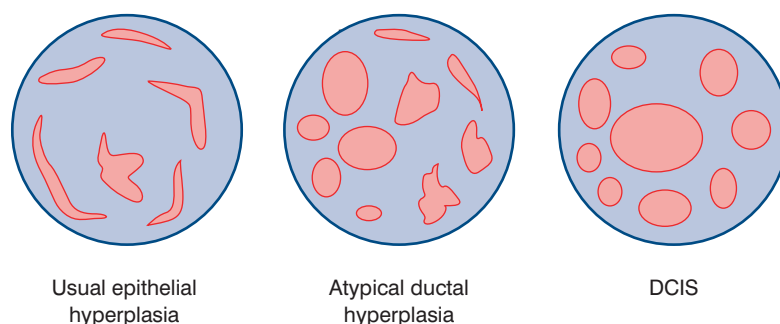


Figure 25 Illustration of the architectural growth pattern differences between ductal carcinoma in situ, atypical ductal hyperplasia and florid hyperplasia of usual type. (Reproduced with permission from Page DL, Rogers LW. Combined histologic and cytologic criteria for the diagnosis of mammary atypical ductal hyperplasia. *Human Pathology*, 1992, 23: 1095–1097).

Pathology Reporting of Breast Disease

Table 2 Comparison of histological features of ductal hyperplasia and ductal carcinoma in situ (DCIS)

Histological features	Usual type hyperplasia	Atypical ductal hyperplasia	Low nuclear grade DCIS
Size	Variable size but rarely extensive unless associated with other benign processes such as papilloma or radial scar	Usually small (<2–3 mm) unless associated with other benign processes such as papilloma or radial scar	Rarely less than 2–3 mm and may be very extensive
Cellular composition	Mixed; luminal epithelial cell and spindle shaped basal cells* present. Lymphocytes and macrophages may also be present. Myoepithelial hyperplasia may occur around the periphery	May be uniform cell population, but merges with areas of usual type hyperplasia within the same duct space. Spindle shaped cells may intermingle with the proliferating cells	Single cell population. Spindle shaped basal cells not seen. Myoepithelial cells usually in normal location around duct periphery but may be attenuated
Architecture	Variable	Micropapillary, cribriform or solid pattern, but may be rudimentary	Well developed micropapillary, cribriform or solid patterns
Lumina	Irregular, often ill defined peripheral slit like spaces are common and a useful distinguishing feature	May be distinct, well formed rounded spaces in cribriform type. Irregular, ill defined lumina may also be present	Well delineated, regular punched out lumina in cribriform type
Cell orientation	Often streaming pattern with long axes of nuclei arranged in parallel to direction of cellular bridges, which often have a ‘tapering’ appearance	Cell nuclei may be at right angles to bridges in cribriform type, forming ‘rigid’ structures	Micropapillary structures with indiscernible fibrovascular cores or smooth, well delineated geometric spaces. Cell bridges ‘rigid’ in cribriform type with nuclei orientated towards the luminal space
Nuclear spacing	Uneven	May be even or uneven	Even
Epithelial/tumour cell character	Small ovoid, but showing variation in shape	Small uniform or medium sized monotonous population present at least focally	Small uniform monotonous population
Nucleoli	Indistinct	Single small	Single small
Mitoses	Infrequent; no abnormal forms	Infrequent; abnormal forms rare	Infrequent; abnormal forms rare
Necrosis	Rare	Rare	If present, confined to small particulate debris in cribriform and/or luminal spaces

Major diagnostic features shown in bold type.

*A mixed epithelial cell population can be demonstrated using immunocytochemistry for low and high molecular weight cytokeratins. Luminal epithelial cells express the low molecular weight cytokeratins 8, 18 and 19. Basal epithelial and myoepithelial cells express the cytokeratins 5 and 14.

13.3 Present with atypia (ductal)

13.3.1 *Classic atypical ductal hyperplasia (as described by Page and Rogers)*

Atypical ductal hyperplasia (ADH)^{7,8} is a rare lesion. Its current definition rests on identification of some but not all features of DCIS.⁹ The difficulties are encountered mainly in distinguishing ADH from the low grade variants of DCIS. The diagnosis of ADH is based on both a qualitative and quantitative assessment of the lesion (Figure 26).¹⁰

The *qualitative* assessment is based on cytological features and architectural growth pattern. These include:

- a uniform monomorphic luminal epithelial cell population (CK8, 18, 19 positive)
- an even cellular distribution
- secondary lumina, some of which are rigid whereas others are tapering
- hyperchromatic nuclei
- cribriform, micropapillary or solid growth pattern.

The *quantitative* assessment is based on assessment of lesion size:

- areas of ADH are usually small and not exceeding 2–3 mm in size. **Proliferations with high grade cytology (with or without necrosis) qualify as DCIS, regardless of size or quantity of epithelial proliferation.**

The diagnosis of ADH is made in those cases in which a diagnosis of DCIS is seriously considered but where the architectural, cytological and quantitative features do not amount to a confident diagnosis of DCIS.

If a diagnosis of ADH is contemplated, extensive sampling and/or levels should be undertaken to search for more evidence to establish an unequivocal diagnosis of DCIS.

Table 2 provides details of features to help distinguish ADH from usual type hyperplasia and DCIS.

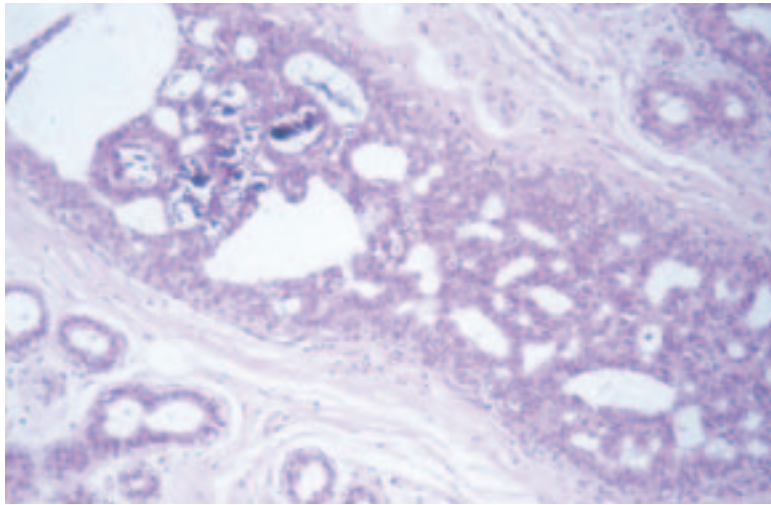
13.3.2 *Useful rules of thumb to distinguish ADH from DCIS*

- Restrict diagnosis of ADH to those cases in which DCIS is seriously considered but where the features are not sufficiently developed to make a confident diagnosis.
- DCIS usually extends to involve multiple duct spaces. If a lesion with features of ADH extends widely, the diagnosis of ADH should be questioned.

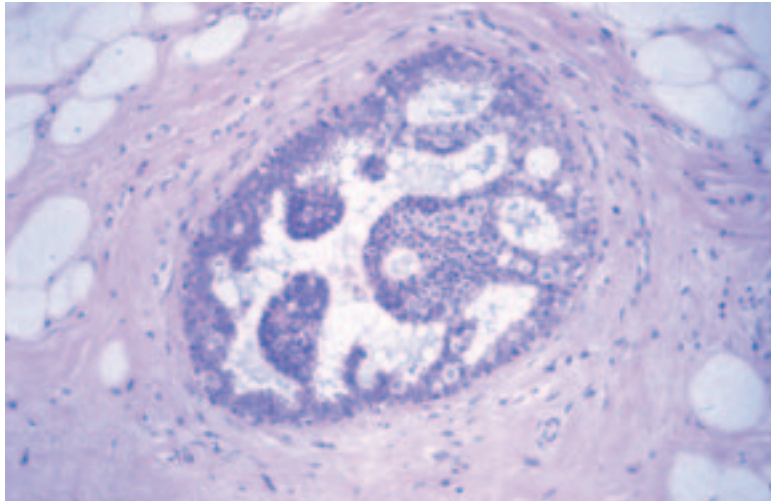
13.4 Atypical lobular hyperplasia and lobular carcinoma in situ (in situ lobular neoplasia)

Atypical lobular hyperplasia (ALH) and lobular carcinoma in situ (LCIS) have traditionally been separated as distinct entities (Figure 27).^{11–13} The difference has been on the basis of cytological and quantitative features relating to the extent of lobular involvement. The justification for separating the entities has been the differing risks of subsequent invasive cancer,¹³ but molecular analysis suggests that biologically the two appear to be essentially similar. ALH is a neoplastic not a hyperplastic prolif-

(a)



(b)



(c)

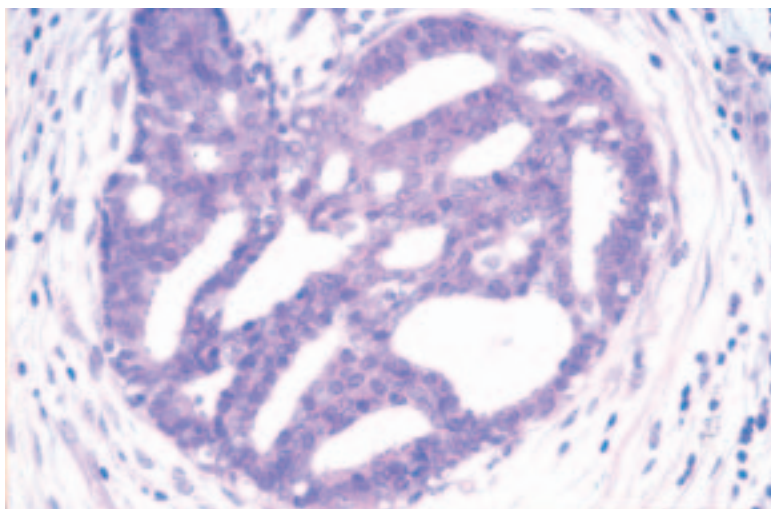
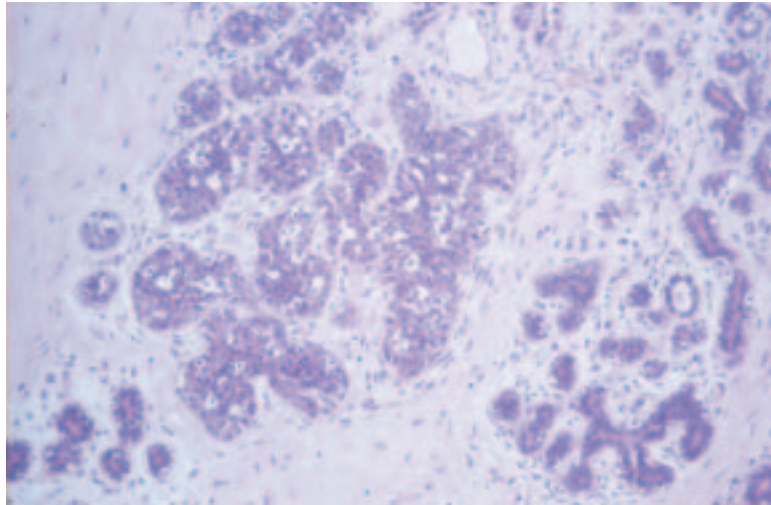


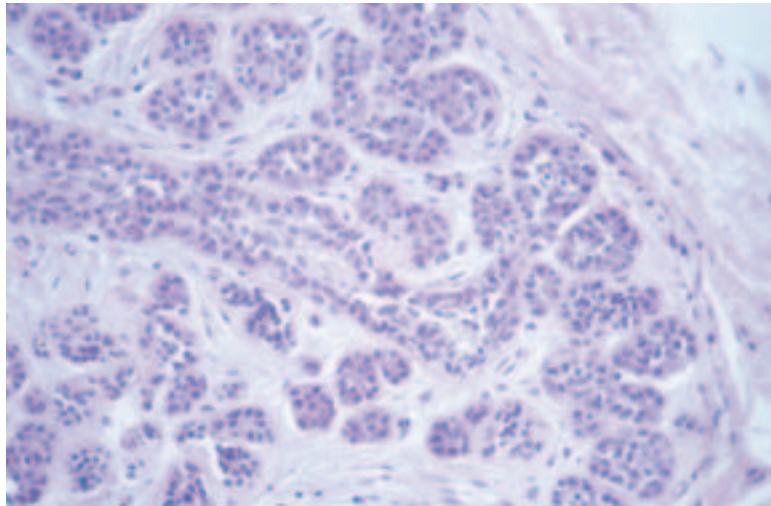
Figure 26 (a–c) Three examples of lesions classified as atypical ductal hyperplasia. All were microfocal (<3 mm in size), and each exhibits many of the features of low grade DCIS.

Figure 27 Examples of the spectrum of lobular neoplasia extending from atypical lobular hyperplasia (a and b), which show incomplete filling and lack of marked distortion of the involved lobular unit, through to florid involvement of a lobular unit in lobular carcinoma in situ with complete filling and marked distortion of the lobular unit (c and d). In all forms, there may be pagetoid extension in adjacent duct spaces (e and f).

(a)



(b)



(c)

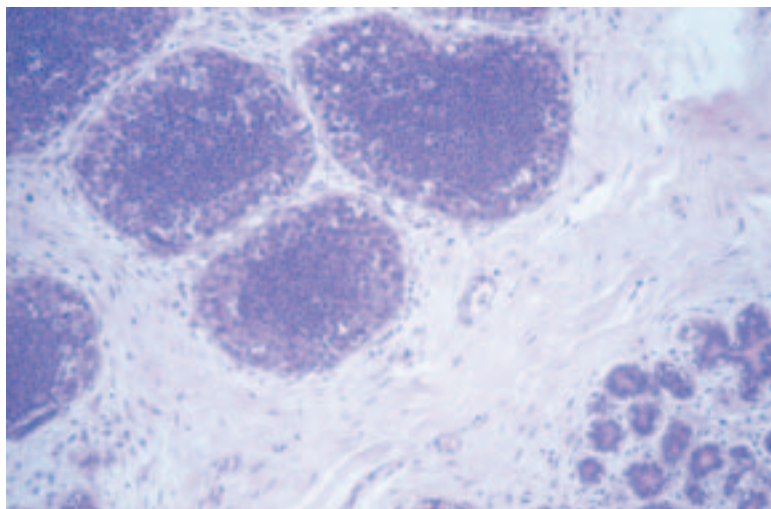
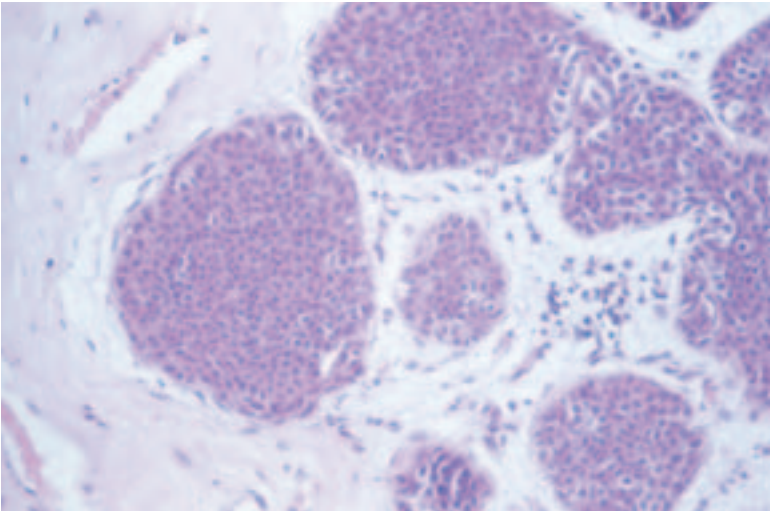
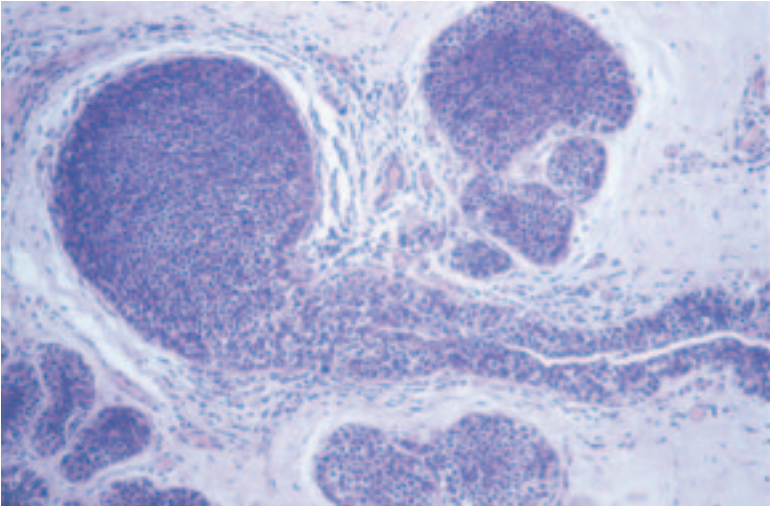


Figure 27 (a-f) Continued.

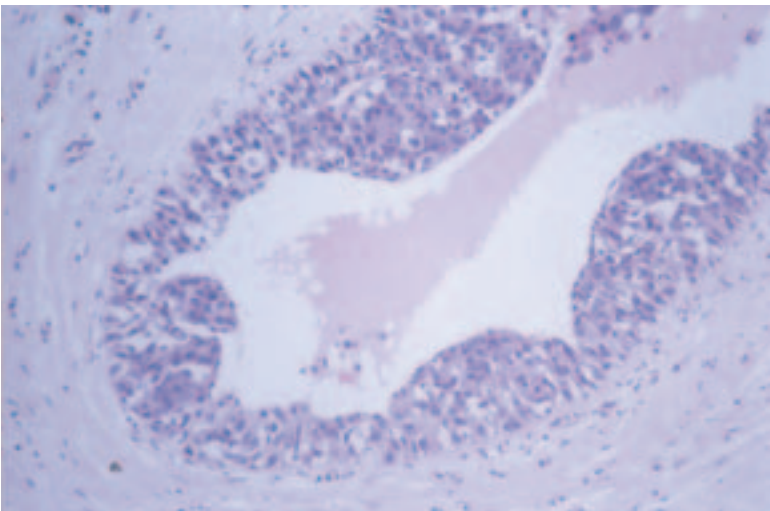
(d)



(e)



(f)



eration. In view of the subjective nature of separating ALH from LCIS, the lack of criteria that allow a different management approach and the similar molecular profiles, these lesions are now commonly grouped together as ‘lobular neoplasia’ (in situ lobular neoplasia). Very mild forms of ALH can be found in association with fibrocystic change, involution and otherwise normal breast tissue. No attributable risk has been shown for these mild forms and such lesions are often disregarded.

In situ lobular neoplasia is characterised by proliferation within terminal duct lobular units of characteristic cells (Figure 27). The defining cell type in in situ lobular neoplasia is round, cuboidal or polygonal with clear or light cytoplasm. Nuclei are small, round to oval and cytologically bland, with an occasional small inconspicuous nucleolus. The nucleus may be indented by an intracytoplasmic vacuole containing mucin. The cells have a high nuclear to cytoplasmic ratio. Mitotic figures and hyperchromatism are not often seen. There is an even distribution of cells and cellular monotony is the rule. Cytoplasmic clear vacuoles are often, although not invariably, present, sometimes having a central mucin blob. There is poor cell cohesion, and pagetoid spread of cells may be present. This proliferation of neoplastic cells above the basement membrane undermines the normal lining epithelial cells. The distension of lobular units may be variable from mild to gross, resulting in either patent lumina or complete obliteration. Table 3 illustrates the differences between DCIS and in situ lobular neoplasia.

Variants, particularly the pleomorphic subtype, are recognised. Loss of E-cadherin membrane reactivity may be useful in distinguishing in situ lobular neoplasia from DCIS. In some more extensive lesions, distinction between in situ lobular neoplasia and DCIS may be difficult or impossible. Such cases should be classified as combined DCIS/in situ lobular neoplasia and indicated as such on the reporting form. On occasions, a regular, evenly spaced monotonous population is seen within both ducts and lobules; in these circumstances, it may also be difficult to classify the lesion as either in situ lobular neoplasia or DCIS. If only scanty terminal ducts are involved and the proliferation is almost entirely lobular, the

Table 3 Distinction of ductal carcinoma in situ (DCIS) from in situ lobular neoplasia

Histological features	DCIS	In situ lobular neoplasia
Cells	Variable, depending on nuclear grade	Small, rounded with granular or hyperchromatic nuclei, inconspicuous nucleoli and high nuclear–cytoplasmic ratio
Intracytoplasmic lumina	Rare	Common
Growth pattern	Very variable, eg solid, comedo, papillary, cribriform	Diffuse monotonous with complete luminal obliteration
Cell cohesion	Usually good	Usually poor
Degree of distension of involved structures	Moderate to great	Slight to moderate
Pagetoid spread into interlobular ducts	Absent	Often present

NB All the features of a lesion should be taken into account when making a diagnosis. No criterion is reliable alone.

lesion is classified as in situ lobular neoplasia. However, distinguishing DCIS from in situ lobular neoplasia may be impossible if both an organoid lobular and ductal component is identified. If both ducts and lobules contain epithelial proliferation of this type, categorisation as both in situ lobular neoplasia and DCIS is recommended to imply the precursor risk of DCIS and the bilateral cancer risk of in situ lobular neoplasia.

14. CLASSIFYING MALIGNANT NON- INVASIVE LESIONS

14.1 Ductal carcinoma in situ

Ductal carcinoma in situ (DCIS) is a unicentric^{1,14} proliferation of epithelial cells with cytological features of malignancy within parenchymal structures of the breast and is distinguished from invasive carcinoma by the absence of stromal invasion across the basement membrane. Despite the name, most DCIS is generally considered to arise from the terminal duct lobular units. The main points of distinction from lobular neoplasia are described in Table 3. Features in favour of DCIS are the slightly larger cell size, readily visible cell membranes, cytoplasmic basophilia, variation in cellular arrangement and size, greater cellular cohesion and lack of intracytoplasmic lumina.

14.1.1 DCIS classification: grade

DCIS varies in cell type, growth pattern and extent of disease and is now considered to represent a group of related in situ neoplastic processes. Classification has historically been according to growth pattern, but has been carried out with little enthusiasm owing to the perceived lack of reproducibility and lack of clinical relevance. Lesions of high nuclear grade are recognised to be clinically more aggressive. Distinguishing between subtypes of DCIS is also of value for correlating pathological and radiological appearances, improving diagnostic consistency, assessing the likelihood of associated invasion and determining the probability of local recurrence. Various systems have been described, based on combinations of cell morphology, architecture (including polarisation of cells) and the presence of necrosis.^{15,16} Necrosis can be identified by the presence of cell ghosts and is eosinophilic and granular in nature. Karyorrhectic debris is seen. The definition of necrosis does not include single apoptotic individual cells.

A high power lens (40×) should be used to compare the size of tumour cell nuclei with normal epithelial nuclear size and red blood cell size.¹⁷

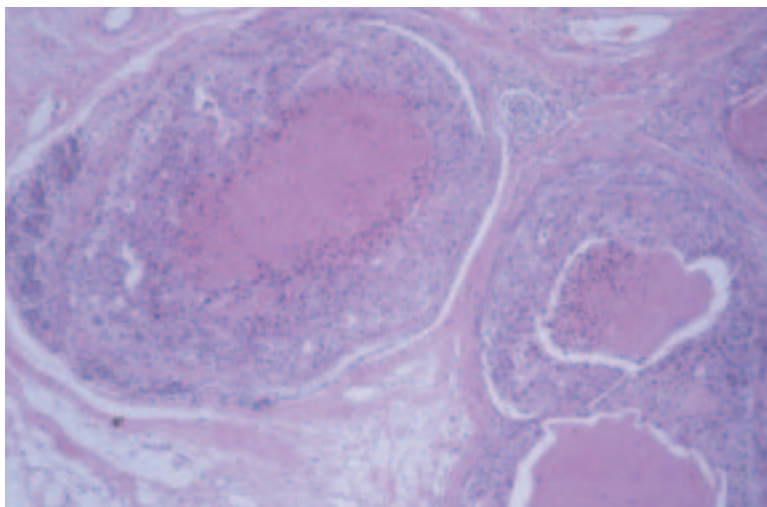
Other features such as mitotic count, presence of prominent nucleoli and polarisation of nuclei may be helpful in assigning grade. In particular, a high mitotic count is very rare in DCIS not of high histological grade.

High nuclear grade DCIS

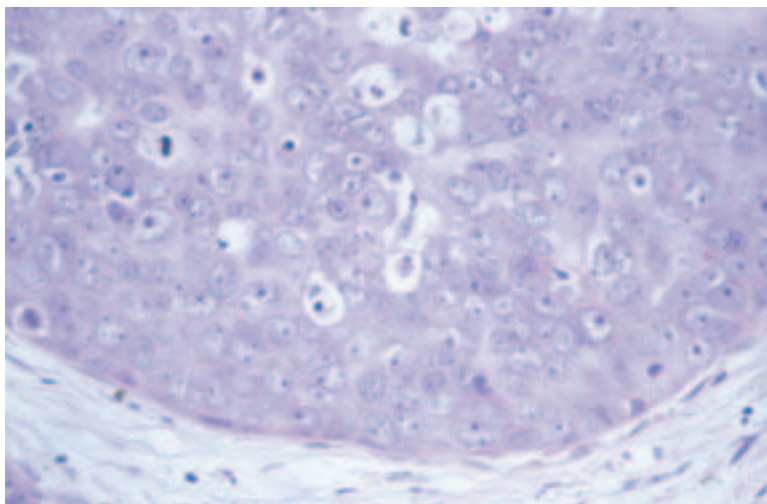
Cells have pleomorphic, irregularly spaced and, usually, large nuclei exhibiting marked variation in size with irregular nuclear contours, coarse chromatin and prominent nucleoli (Figure 28). Nuclei are typically large and greater than three times the size of erythrocytes. Mitoses are usually frequent and abnormal forms may be seen. If mitoses are prominent, there is a high likelihood that a case is of high grade. High grade DCIS may exhibit several growth patterns. It is often solid with comedo type central necrosis, which frequently contains deposits of amorphous calcification. Sometimes, a solid proliferation of malignant cells fills the duct without necrosis, but this is relatively uncommon and may be confined to nipple/lactiferous ducts in cases presenting with Paget's disease of the nipple. High nuclear grade DCIS may also exhibit micropapillary and cribriform

Figure 28 (a–c) High grade DCIS is composed of large cells showing marked nuclear pleomorphism arranged in solid sheets. Frequently, there is central necrosis of the duct space which often undergoes linear casting type microcalcification.

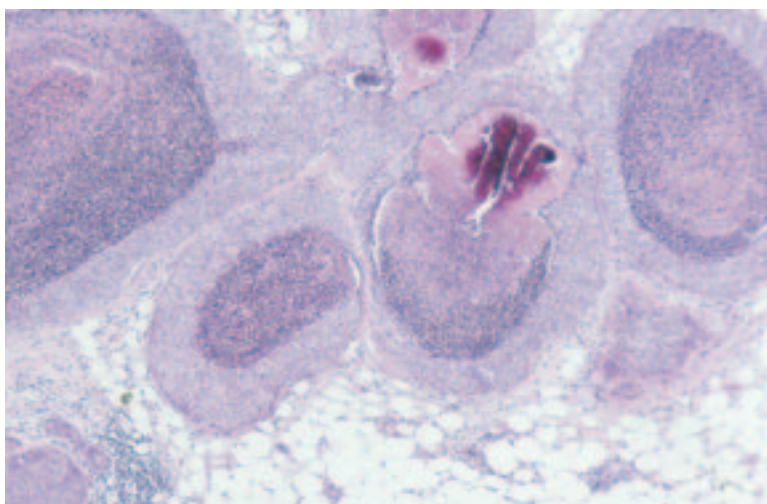
(a)



(b)



(c)



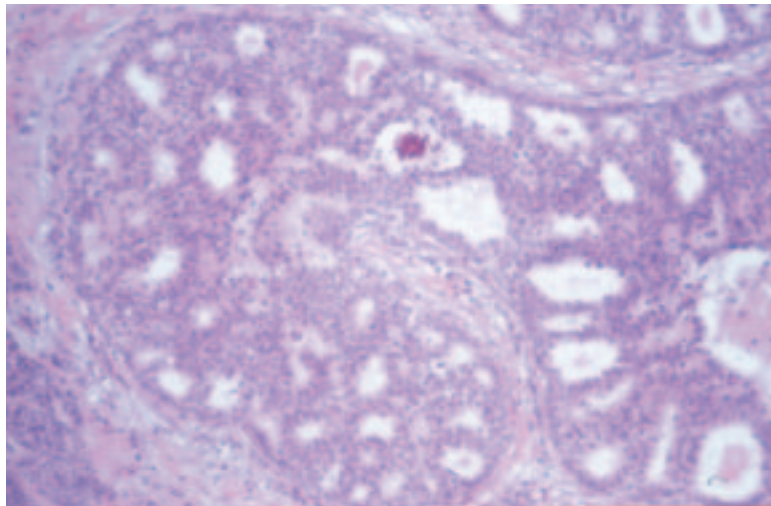
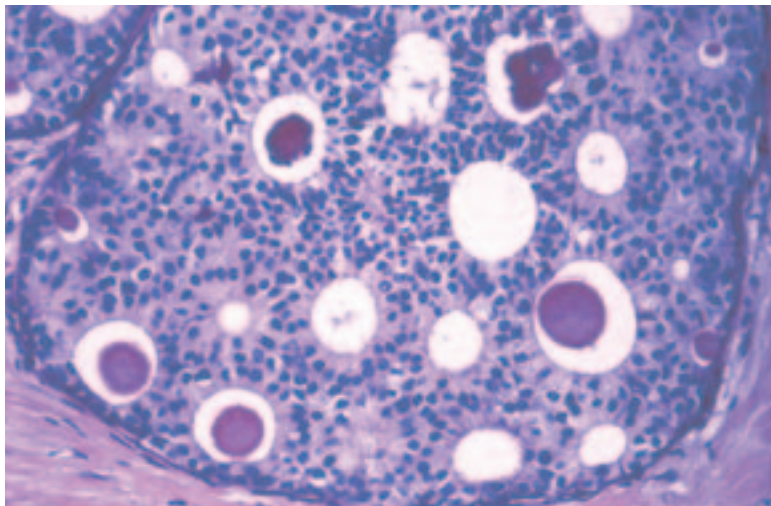


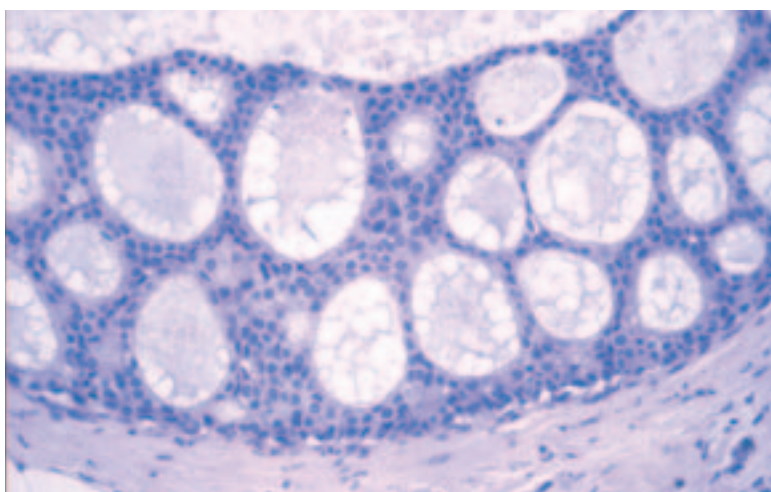
Figure 29 An example of intermediate grade DCIS that has moderate sized nuclei and that shows some focal necrosis.

Figure 30 Examples of low grade DCIS with small regular cells, a structured cribriform (a and b) or micropapillary (c and d) growth pattern and lack of associated necrosis. There may be associated punctuate microcalcification of the secretions present in secondary luminal glandular spaces (a).

(a)



(b)



patterns frequently associated with central comedo type necrosis. Unlike low nuclear grade DCIS, there is rarely any polarisation of cells covering the micropapillae or lining the intercellular spaces.

Intermediate nuclear grade DCIS

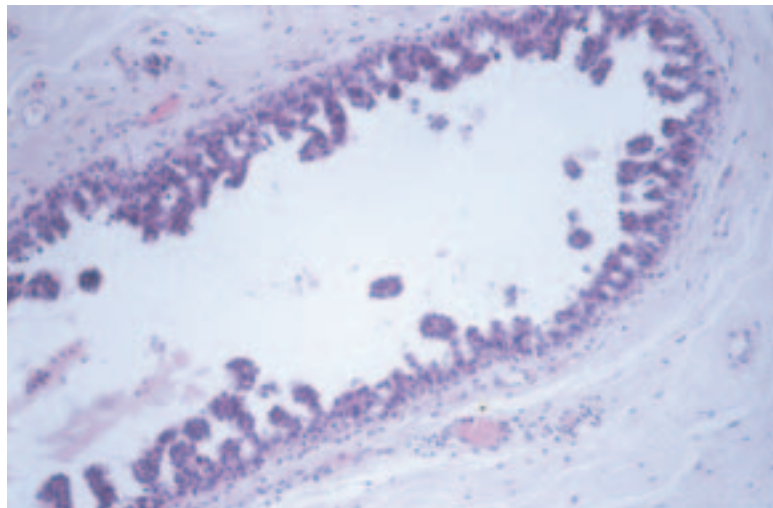
These types cannot be assigned readily to the high or low nuclear grade categories. The nuclei show moderate pleomorphism, less than that seen in the high grade disease, but lack the monotony of the small cell type (Figure 29). The nuclei are typically larger than those seen in low grade DCIS and are between two and three times the size of an erythrocyte. The nuclear to cytoplasmic ratio is often high, and one or two nucleoli may be identified. The growth pattern may be solid, cribriform or micropapillary, and the cells usually exhibit some degree of polarisation covering papillary processes or lining intercellular lumina. Clear cell or apocrine types often fall into this category.

Low nuclear grade DCIS

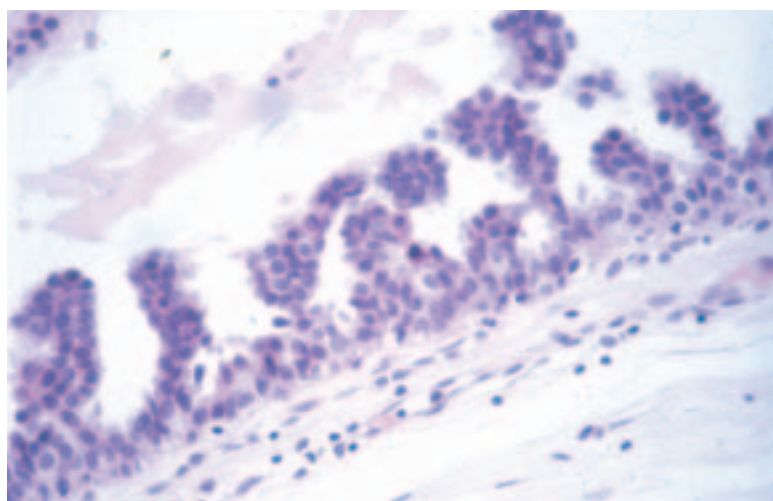
Low grade DCIS is composed of monomorphic, evenly spaced cells with rounded, centrally placed nuclei and inconspicuous nucleoli (Figure 30).

Figure 30 (a–d) Continued.

(c)



(d)



The nuclei are usually, but not invariably, small and are typically one to two times the size of an erythrocyte. Mitoses are few and there is rarely individual cell necrosis. These cells are generally arranged in micropapillary and cribriform patterns. Both patterns are frequently present within the same lesion, although the cribriform pattern is more common and tends to predominate. There is usually polarisation of cells covering the micropapillae or lining the intercellular lumina. Less frequently, low grade DCIS has a solid pattern.

Mixed types of DCIS

A small proportion of cases of DCIS exhibit features of differing nuclear grade. Such variation in cell type is unusual, but, if present, the case should be classified by the highest nuclear grade present.

Rarer subtypes of DCIS

Other rare, but morphologically distinct, subtypes of DCIS are recognised. There is, however, no firm evidence to support the distinction of special DCIS types from commoner DCIS forms, with the exception of encysted papillary carcinoma in situ and apocrine DCIS. The practical problem of interobserver disagreement in distinction of some special DCIS subtypes, particularly apocrine and micropapillary DCIS, has led to some suggesting a working classification of DCIS with five subtypes: high, intermediate and low grade with, in addition, apocrine and micropapillary DCIS as separate categories. Simultaneous use of the grading system described above and subtyping according to architecture is recommended.

14.1.2 DCIS classification: growth pattern

Apocrine DCIS^{18,19}

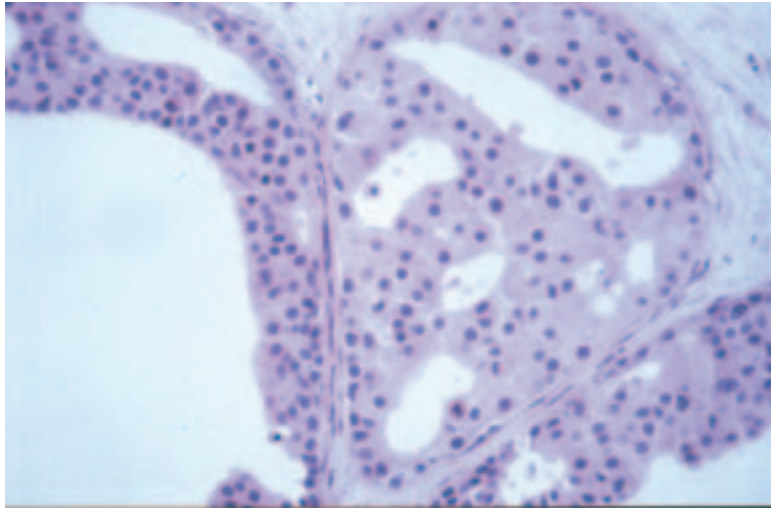
The tumour cells show abundant granular cytoplasm, moderate to severe cytological atypia and central necrosis (Figure 31). Apical snouting (cytoplasmic protrusions) is not always seen. The cells may sometimes be highly atypical. In some cases, no necrosis may be evident. The suggested diagnosis of apocrine DCIS should be made with caution, particularly in the absence of comedo type necrosis. It may be extremely difficult to distinguish atypical apocrine hyperplasia from low grade apocrine DCIS. The degree of cytonuclear atypia, the extent of the lesion and altered architectural growth pattern are helpful features used to make this decision. Mitoses are also a helpful feature as these are very infrequent or absent in atypical apocrine proliferations.

Benign apocrine change is, of course, frequent in breast biopsy material and is recognised to show nuclear atypia, which should not be interpreted as DCIS. Atypical apocrine adenosis may also mimic apocrine DCIS or even invasive apocrine carcinoma. Identification of mitoses or periductal inflammation and fibrosis may be helpful as they are rarely seen in atypical apocrine hyperplasia or apocrine proliferations other than DCIS.

Encysted (intracystic) papillary carcinoma in situ²⁰

This is a rare but distinctive form of DCIS, which is more common in older women. It carries an excellent prognosis if confined within the capsule without surrounding DCIS or foci of invasion. The presence of associated DCIS in the surrounding tissue is recognised to be of significance regarding local recurrence and should be recorded. Encysted

(a)



(b)

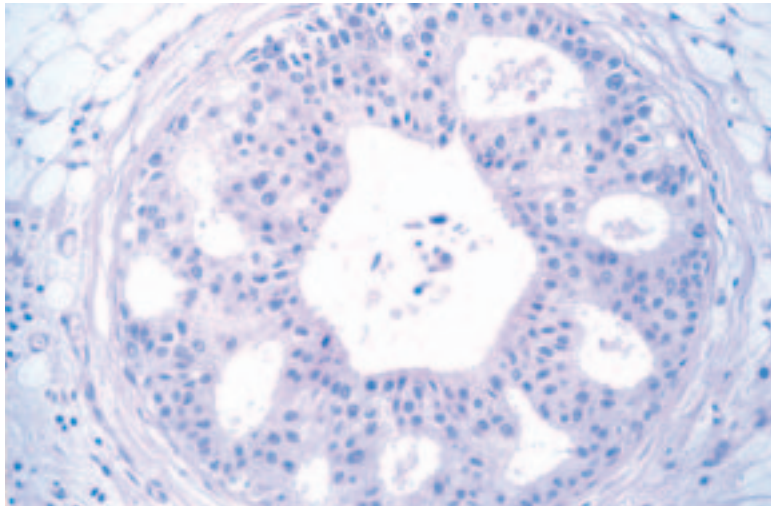


Figure 31 (a and b) Apocrine DCIS is distinguished from apocrine change by its extent and the presence of both cytonuclear atypia and abnormal growth patterns.

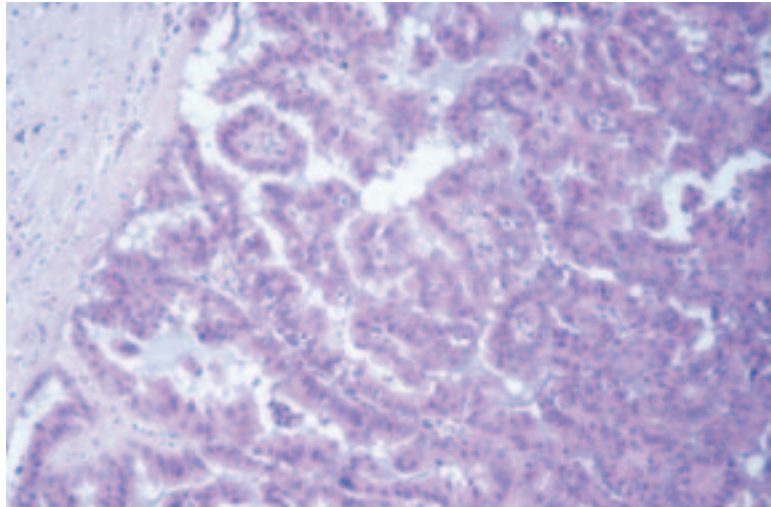
papillary carcinoma in situ is usually circumscribed and accompanied by a hyalinised fibrous wall, giving an intracystic (encysted) appearance. Adjacent to the fibrous capsule, haemosiderin (or haematoidin) pigment is often seen. Encysted papillary carcinoma has a papillary structure with fibrovascular cores (Figure 32); however, these may be absent in at least part of the lesion. Other forms of DCIS, usually of micropapillary or cribriform architecture, may accompany it.

Clear cell DCIS

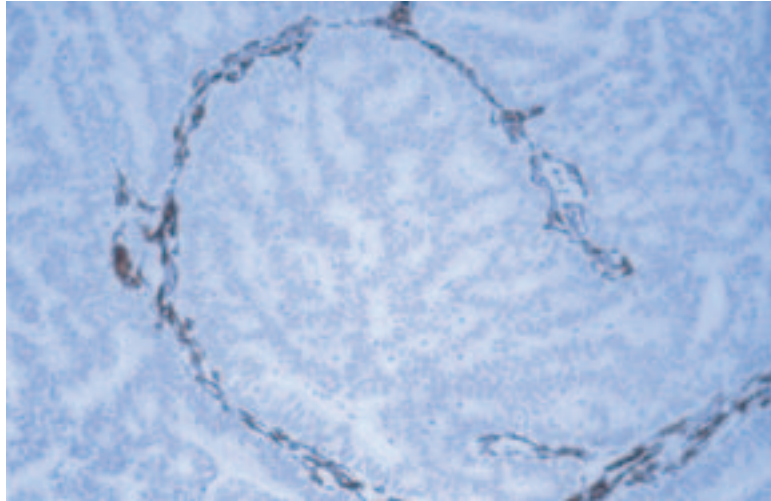
This is an intraductal proliferation of neoplastic cells with optically clear cytoplasm and distinct cell margins forming cribriform and solid structures. Central necrosis may be present. This may be mimicked by poor fixation in other forms of DCIS and care should be taken to achieve optimum fixation of all breast samples.

Figure 32 Papillary carcinoma in situ retains a papillary growth pattern (a) but lacks a coexisting myoepithelial layer covering the fibrovascular fronds; (b) smooth muscle actin staining showing lack of myoepithelial cells. The epithelial tumour cells may show a range of degrees of cytonuclear atypia and growth pattern (c).

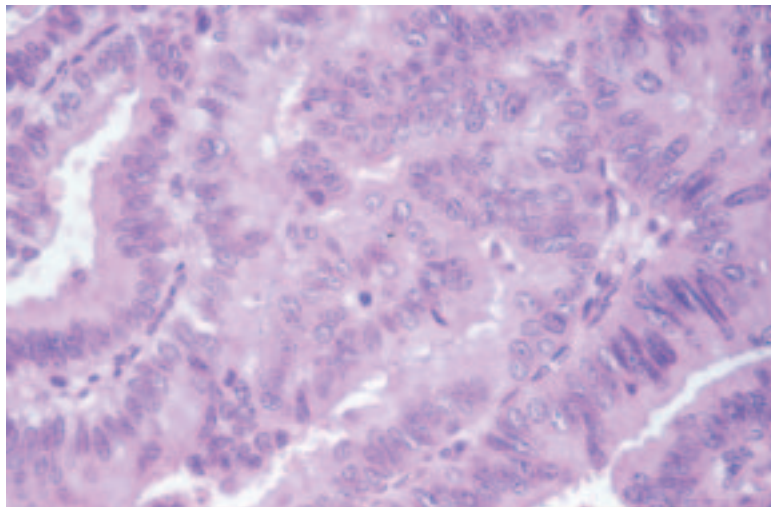
(a)



(b)



(c)



Signet ring DCIS²¹

This is a very rare variant characterised by the proliferation of signet ring cells in solid or papillary growth patterns. The cytoplasm stains positive with diastase resistant periodic acid–Schiff (PAS) or Alcian blue.

Neuroendocrine DCIS

The lesion has an organoid appearance with prominent argyrophilia, resembling a carcinoid tumour. The neoplastic cells may be arranged in a solid pattern or may be papillary forming tubules, pseudorosettes, palisades or ribbons. Where solid, the proliferation is nearly always punctuated by fine fibrovascular cores. An eosinophilic cytoplasmic granularity or organoid spindle morphology is all supportive of the neuroendocrine phenotype. Because of the lack of microcalcification, these tumours tend to present symptomatically, most commonly in elderly patients with blood stained nipple discharge. Immunohistochemical stains for neuroendocrine markers (chromogranin, PGP9.5, synaptophysin) may be helpful in diagnosis of this subtype of DCIS, which also expresses oestrogen receptor (Figure 33).

Cystic hypersecretory DCIS and mucocoele-like DCIS²²

These types of DCIS are variants of micropapillary DCIS. The cells produce mucinous secretions, which distend involved duct spaces, thereby giving a cystic appearance (Figure 34a and b). Microcalcifications are often a very prominent feature.

Flat DCIS

This lesion is becoming increasingly recognised as an entity and is believed by some authorities to be a variant of micropapillary DCIS. It is particularly related to the spectrum of columnar cell alterations and, as such, presents particular problems of recognition and definition. This range of columnar cell alterations (see section 12.8) extends from common forms of benign blunt duct adenosis/columnar cell alteration through atypical forms to flat in situ carcinoma (Figure 34c).

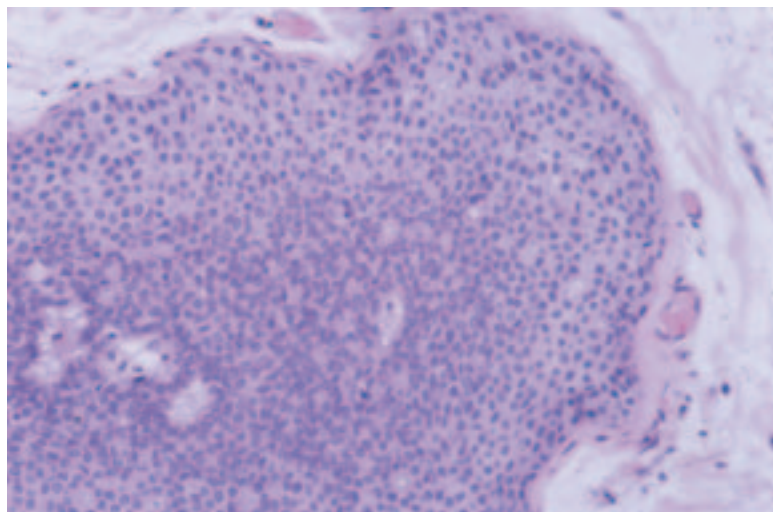
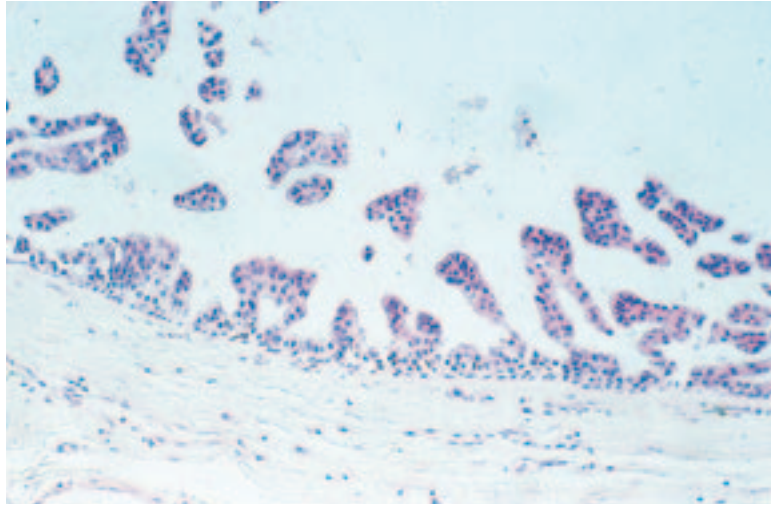
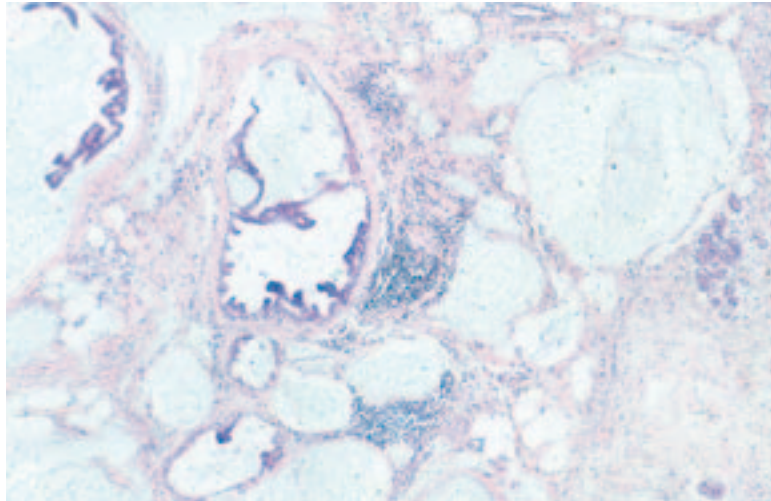


Figure 33 An example of solid/neuroendocrine DCIS which often arises in association with a papillary lesion.

(a)



(b)



(c)

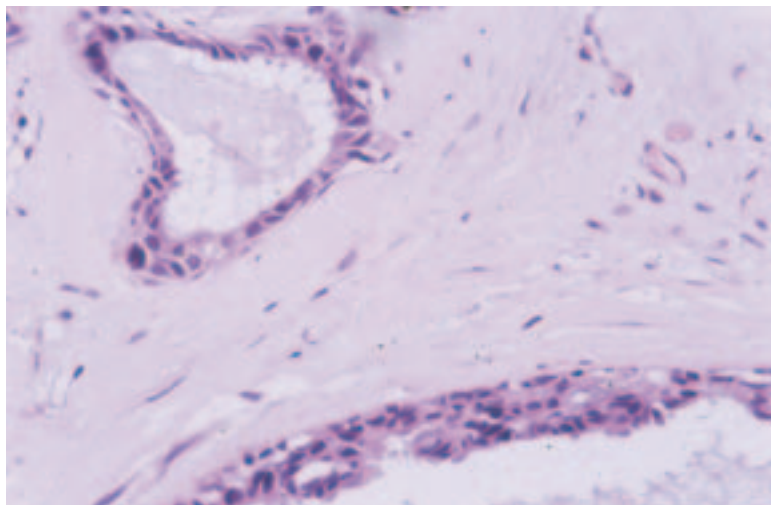


Figure 34 An example of cystic hypersecretory DCIS with a micropapillary growth pattern (a). There is often associated stromal mucin ‘mucocoele like lesion’ (b). Flat DCIS may also be associated with mucin hypersecretion (c).

14.2 Paget's disease of the nipple

In this condition, there are adenocarcinoma cells within the epidermis of the nipple (Figure 35). Epidermal invasion by tumour infiltrating the skin is excluded. Paget's disease of the nipple should be reported regardless of whether or not the underlying in situ or invasive carcinoma is identified. The underlying carcinoma should be recorded separately.

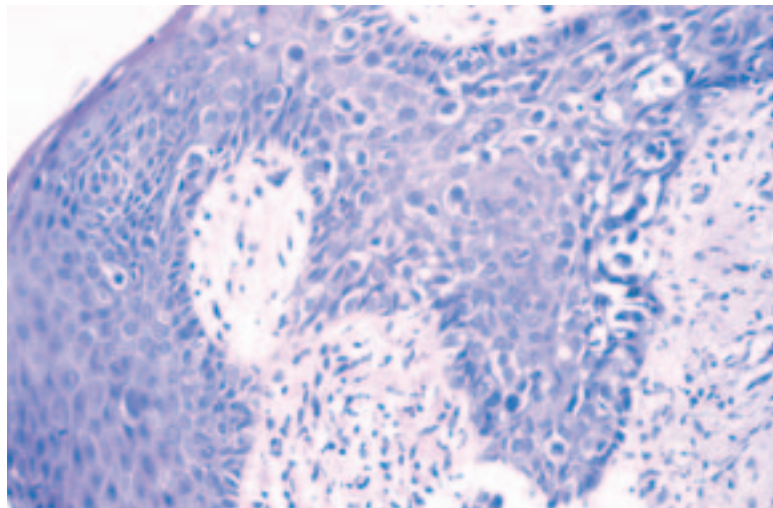
14.3 Microinvasive carcinoma

There is typically a dominant and often extensive DCIS lesion with one or more clearly separate foci of infiltration into non-specialised interlobular stromal tissue, none of which measures more than 1 mm in diameter (Figure 36). Fulfilling these criteria is very uncommon, and if there is doubt about the presence of invasion the case should be classified as pure DCIS only. Microinvasion is very rare in DCIS other than high nuclear grade, and is rare even in high grade disease. Cases of pure high or intermediate nuclear grade DCIS and those with comedo type necrosis should be extensively sampled to exclude microinvasion or larger (> 1 mm) foci of established invasion.

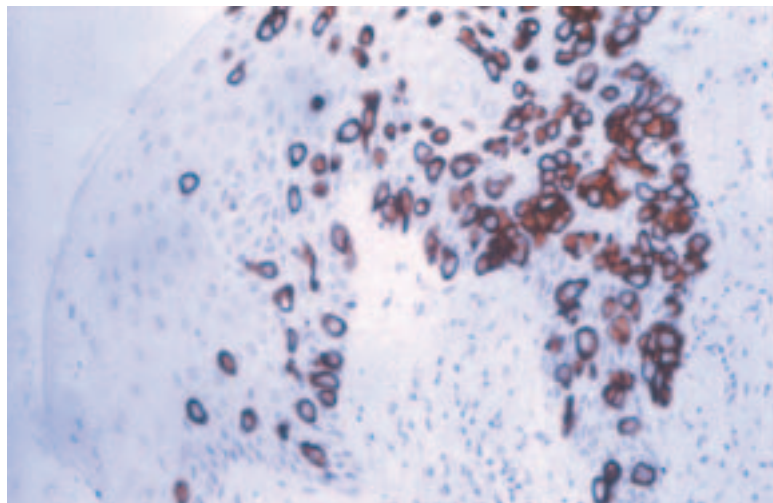
Care should be taken to avoid overdiagnosis of cancerisation of lobules as microinvasive carcinoma. The organoid appearance of cancerisation

Figure 35 (a and b) Paget's disease of the nipple is associated with high grade DCIS involvement of nipple ducts and arises by infiltration of DCIS cells into the nipple epidermis. These cells can be demonstrated using staining for low molecular weight glandular cytokeratins (b).^{7,17,18}

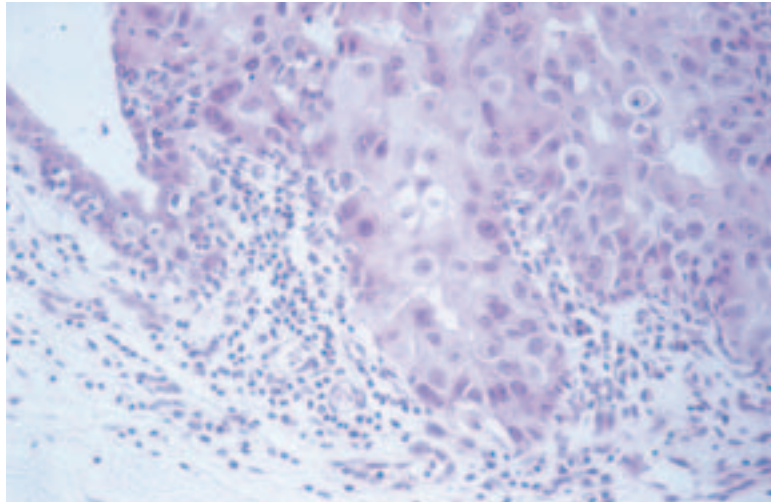
(a)



(b)



(a)



(b)

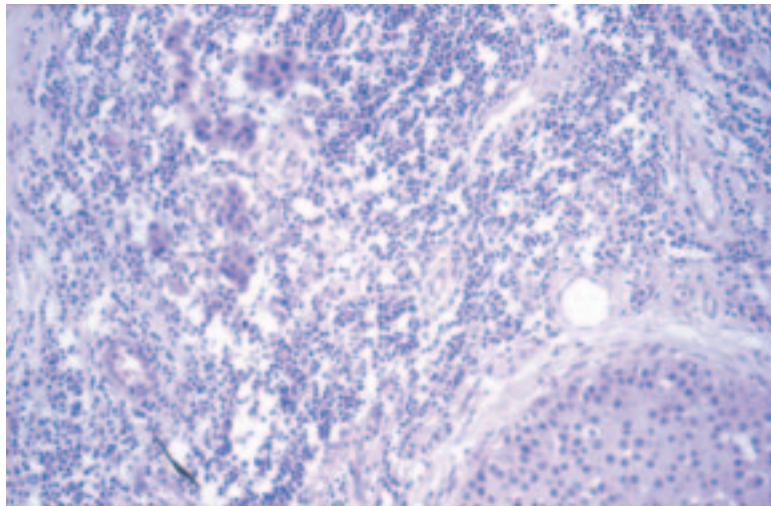


Figure 36 The definition of microinvasive carcinoma is restrictive, and there are cases when definite extension into non-specialised stroma (a) should not be classified as microinvasive carcinoma. This lesion is typically associated with extensive high grade DCIS. Associated inflammatory cell infiltration may help identification of microinvasive carcinoma (b).

of lobules should be sought and deeper H&E sections from the paraffin block are often more helpful than immunohistochemical examination. However, stains that label myoepithelial cells (alpha-smooth muscle actin and myosin or cytokeratin 14) or the basement membrane (laminin and collagen IV) may assist in the diagnosis, as these will be absent on invasion fronts.

15. CLASSIFYING INVASIVE CARCINOMA

Typing invasive carcinomas has prognostic value and provides information on pattern of metastatic spread and behaviour. Caution should be exercised in typing carcinomas in poorly fixed specimens or if they have been removed from patients who have been treated by primary chemotherapy or radiotherapy prior to surgery.

Typing of breast carcinomas has been shown in the NHSBSP external quality assessment (EQA) scheme²³ to be relatively poorly reproducible, and the system has been revised with emphasis on concordance and recognition of pure special types.

15.1 No special type

No or less than 50% special type characteristics are present. This is the commonest category of invasive breast cancer and is often described as ductal cancer, but in view of its lack of specific defining characteristics the term no special type or no specific type is preferred.

15.2 Pure special type

A classic example, showing the hallmark histological features. You should be confident that other pathologists would recognise this case as a pure special type. **The definitions require 90% purity.** Special type tumours in general have characteristic, usually favourable, clinical prognostic characteristics, as described below.

15.3 Mixed tumour type

This is a relatively common pattern of invasive breast carcinoma. The tumour may be heterogeneous in morphology with some characteristic special type areas (**more than 50% but less than 90%**). For example, there may be areas of pure tubular differentiation or one or more characteristics of a special type, but the full combination of features required for pure special type designation (such as a distinctive lobular infiltrative growth pattern with non-lobular cell morphology) is lacking. This is different from pleomorphic lobular carcinoma, and is also different from tumours which include a mixture of specific lobular subtypes. The special type characteristic or area should be identified as an additional feature.

15.4 Morphological type

The more common types are described below.

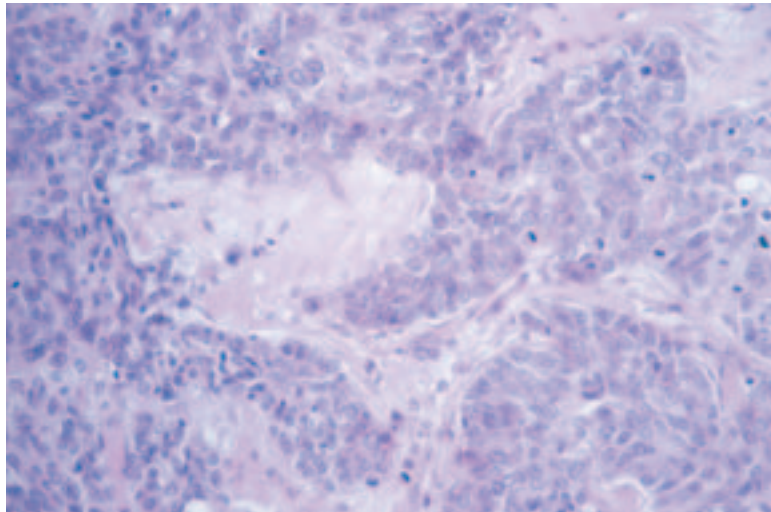
15.4.1 *Ductal/no specific/ special type (ductal NST)*

This group contains infiltrating carcinomas that cannot be entered into any other category on the form, or classified as any of the less common variants of infiltrating breast carcinoma. **The tumour shows less than 50% special type characteristics.** Consequently, invasive ductal carcinomas exhibit great variation in appearance (Figure 37) and are the most common carcinomas, accounting for up to 75% in published series.

15.4.2 *Infiltrating lobular carcinoma*

Infiltrating lobular carcinoma is composed of small regular cells identical to those seen in situ lobular neoplasia. In its classic form, the cells are dissociated from each other or form single files or targetoid patterns around uninvolved ducts (Figure 38). Several variants have been identified in addition to this classic form, but in each case the cell type is the same (Figure 39):

(a)



(b)

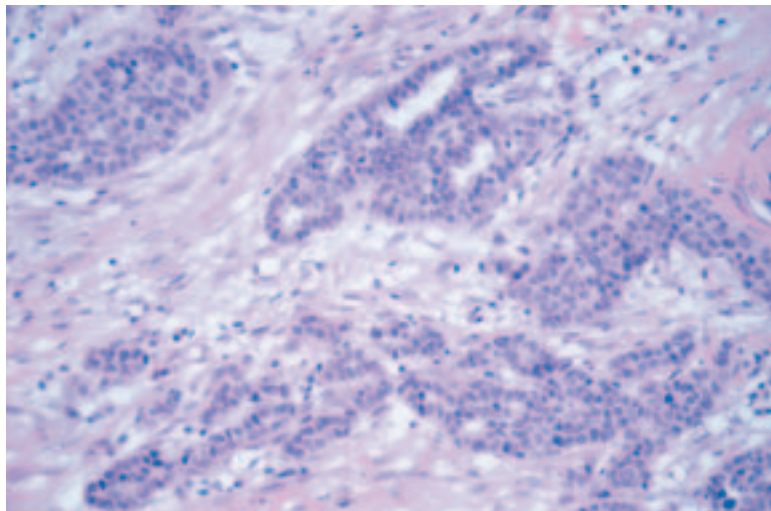
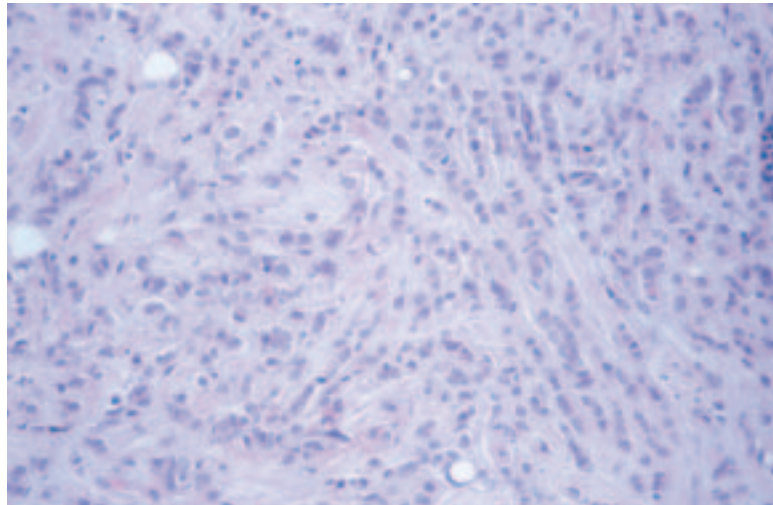


Figure 37 (a and b) Tumours of no special type (ductal NST) lack the presence of special type characteristics in the majority of their structure. Tumours with between 50% and 90% special type characteristics should be classified as mixed.

- a. the **tubulolobular** type exhibits microtubular formation as part of the classic pattern. This is different morphologically from tumours that show mixtures of typical tubular and classic lobular carcinoma, which should be classified as mixed
- b. the **alveolar** variant exhibits small aggregates of 20 or more cells
- c. the **solid** variant consists of sheets of cells with little stroma
- d. the **pleomorphic** variant is uncommon and exhibits the growth pattern of classic lobular carcinoma throughout, but the cytological appearances, although retaining lobular characteristics, are more pleomorphic than those seen in classic invasive lobular carcinoma.

Lobular mixed type lesions consist of mixtures of the above subtypes of lobular carcinoma.

(a)



(b)

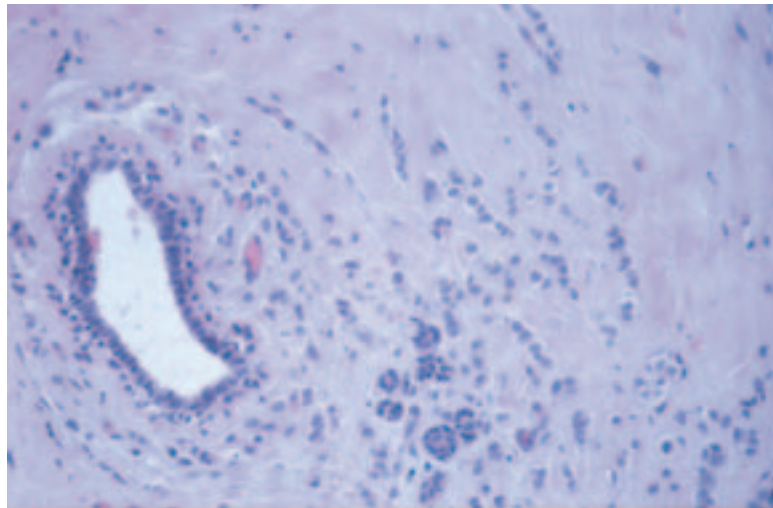


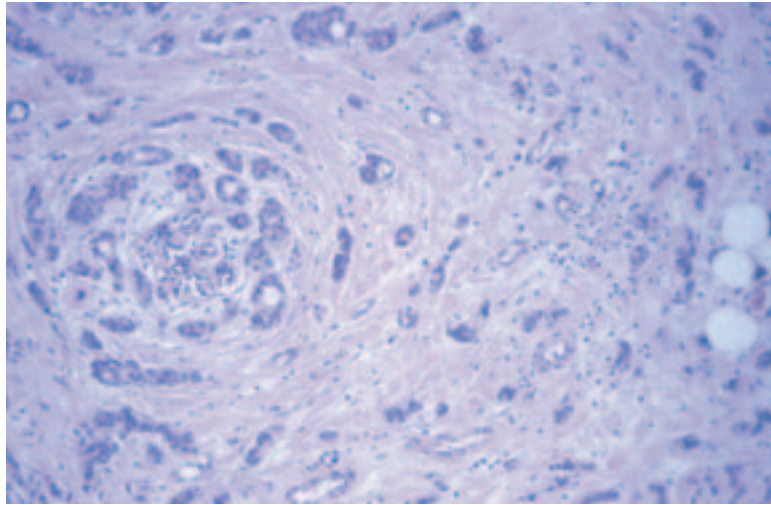
Figure 38 (a and b) Examples of classic invasive lobular carcinoma showing infiltration of cells in files with preservation of the background tissue structure.

At least 90% of the tumour should exhibit one or more of the above patterns to be classified as infiltrating lobular.

15.4.3 Tubular carcinoma

Tubular carcinomas are composed of round, ovoid or angulated single layered tubules in a cellular fibrous or fibroelastotic stroma (Figure 40). The neoplastic cells are small, uniform and may show cytoplasmic apical snouting. Nuclei should not show high grade degrees of atypia. At least 90% of the tumour should exhibit the classic growth pattern to be classified as tubular. However, if the coexistent carcinoma is solely of the invasive cribriform type, then the tumour should be typed as tubular if the tubular pattern forms over 50% of the lesion.

(a)



(b)

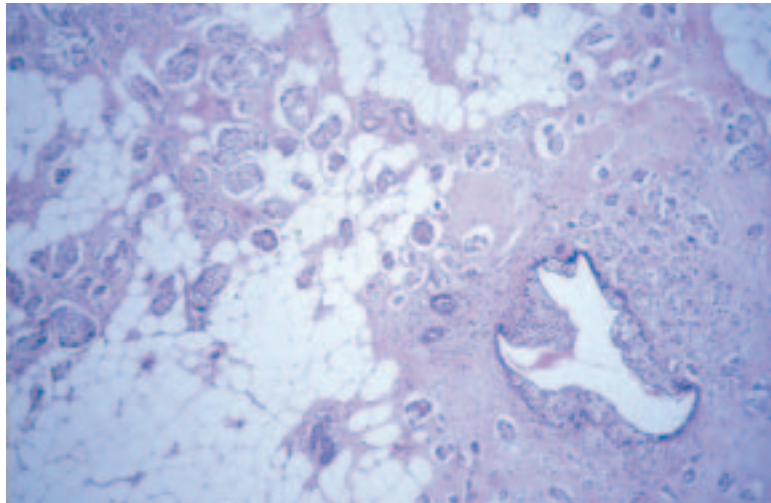


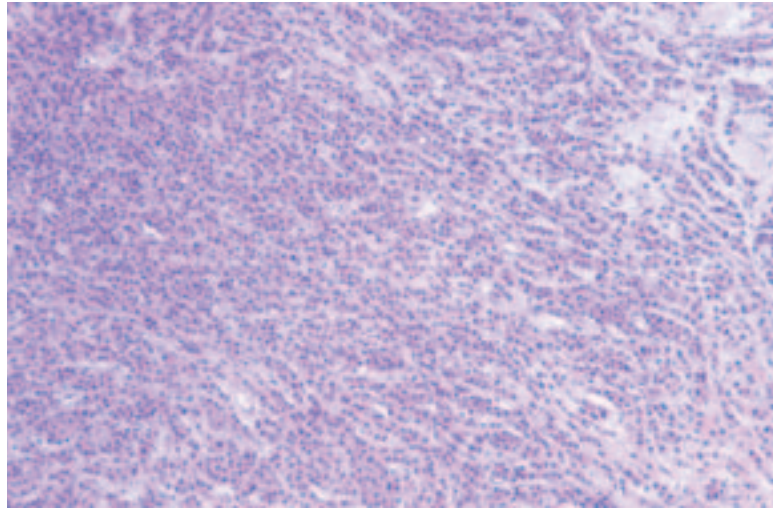
Figure 39 (a–d) Examples of invasive lobular carcinoma variants including tubulolobular (a), alveolar (b), solid (c) and pleomorphic (d). All exhibit the typical discohesive nature and share cytomorphological characteristics with classic lobular carcinoma.

15.4.4 Invasive cribriform carcinoma

This tumour is composed of masses of small regular cells, as seen in tubular carcinoma. The invasive islands, however, exhibit a cribriform rather than a tubular appearance (Figure 41). Apical snouting is often present. Nuclei should not show high grade degrees of atypia. More than 90% of the lesion should exhibit the cribriform appearance except in cases where the only coexistent pattern is tubular carcinoma, when over 50% must be of the cribriform appearance in order to be classified as of invasive cribriform type.

If a diagnosis of invasive cribriform carcinoma is preferred, the ‘tubular’ box should be ticked and appropriate comment made under ‘Comments/additional information’.

(c)



(d)

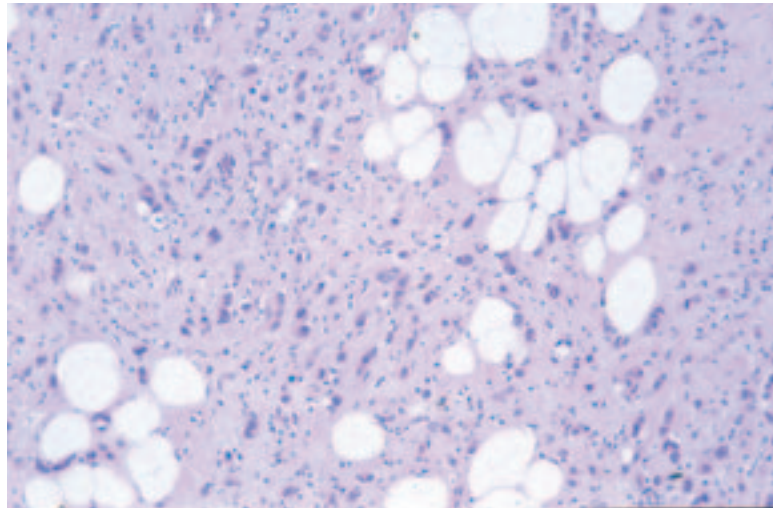


Figure 39 (a–d) Continued.

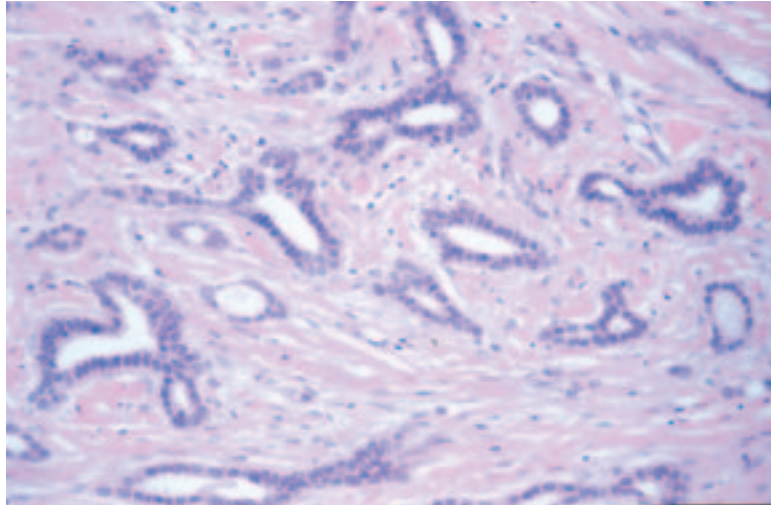
15.4.5 Medullary like carcinoma (medullary/atypical medullary carcinoma)

Tumours of medullary and atypical medullary types should be recorded as special type on the reporting form and the type component recorded. The term medullary like carcinoma is now preferred to encompass both types. The key components of these lesions are syncytial interconnecting masses of grade 3 tumour typically having large vesicular nuclei and prominent nucleoli (Figure 42). The stroma always contains large numbers of lymphoid cells. These features must be present in 90% or more of the tumour.

The border of the tumour is predominantly pushing or well defined. The whole tumour must exhibit these features to be typed as medullary. Surrounding in situ elements are very uncommon.

The term **atypical medullary carcinoma** has been used for lesions that do not have an entirely well defined pushing margin (Figure 42). The

(a)



(b)

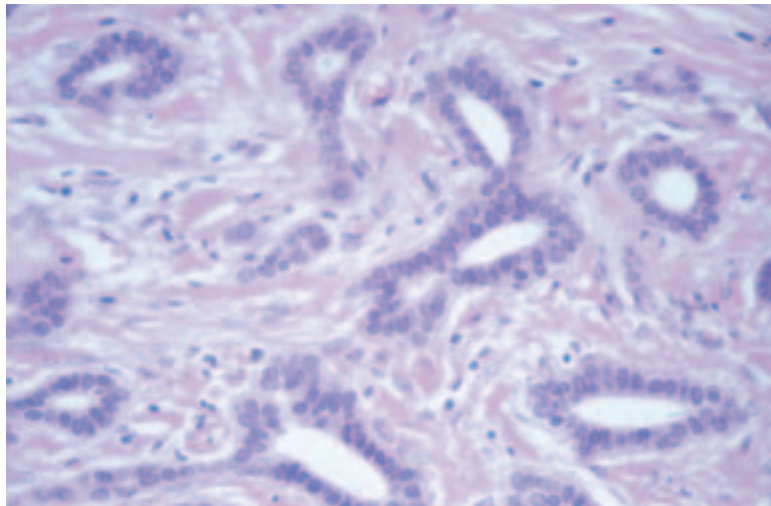


Figure 40 (a and b) An example of tubular carcinoma showing characteristic angular tubular structures and a cellular stroma.

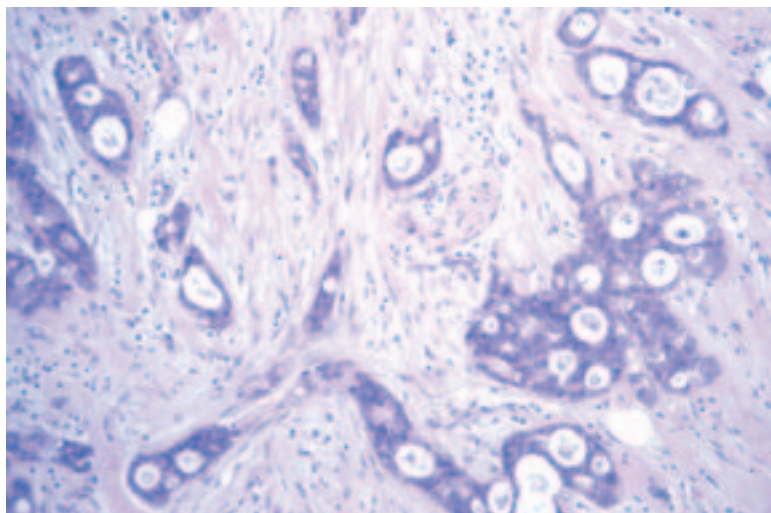
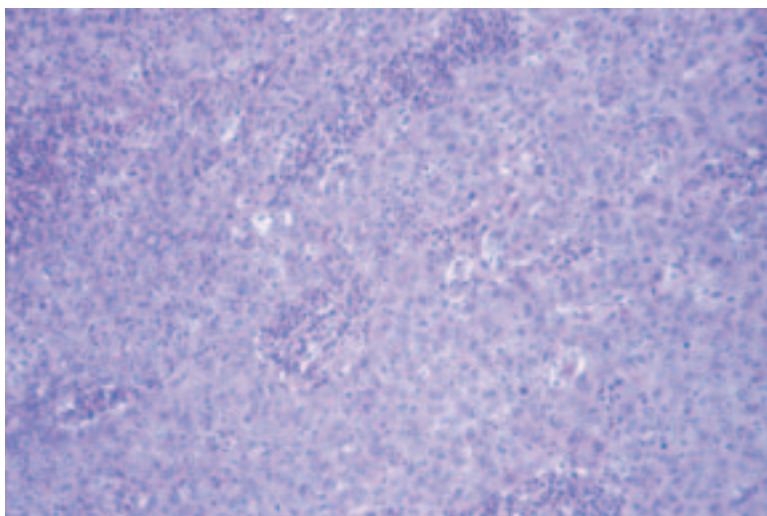
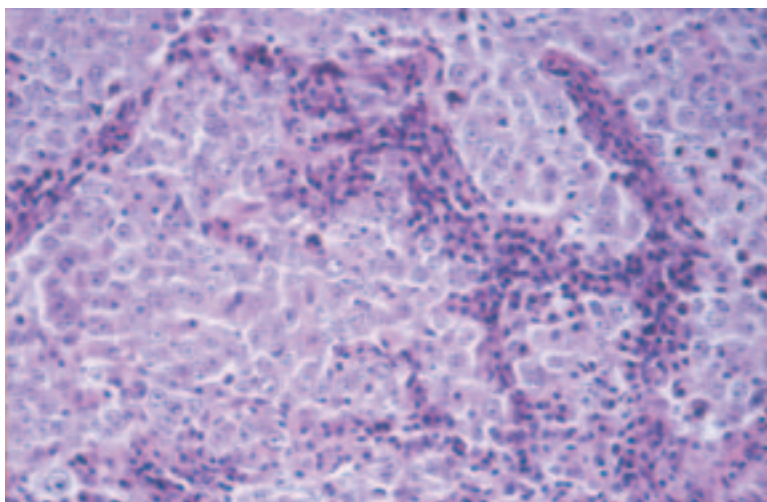


Figure 41 An example of invasive cribriform carcinoma.

(a)



(b)



(c)

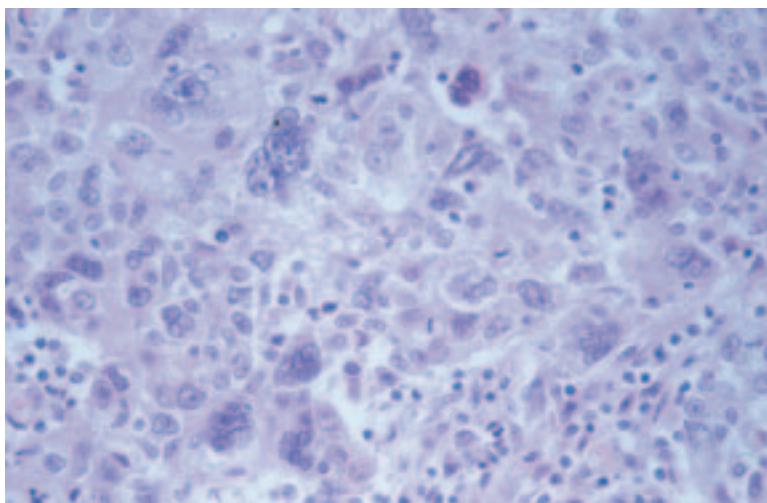
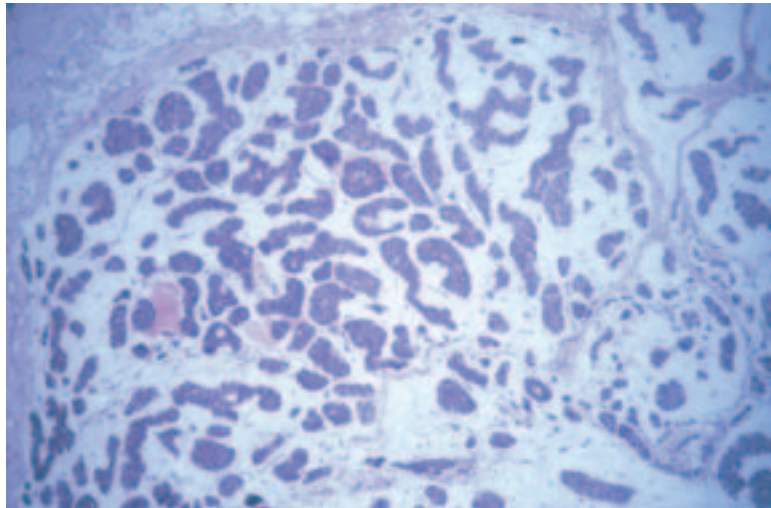


Figure 42 (a–c) An example of medullary like carcinoma (the preferred term for medullary and atypical medullary like carcinomas) with a syncytial growth pattern, pushing margin, lymphocyte rich stroma and high cytonuclear grade.

atypical medullary group has been defined by both Fisher et al.²⁴ and Ridolfi et al.²⁵ These tumours may show less lymphoid infiltration and less circumscription or areas of dense fibrosis, while still having the other features of a medullary carcinoma. A well circumscribed tumour is also classified as atypical medullary if up to 25% is composed of 'ductal' type and the rest comprises classic medullary carcinoma. If in doubt, the tumour should be classified as being 'ductal NST'.

Recently, an increased frequency of tumours exhibiting some medullary features (high grade, pushing margins, lymphocyte rich stroma) has been found in patients with inherited *BRCA1* gene mutations. The tumours cross the spectrum of pure medullary, atypical medullary and ductal NST with a lymphocyte rich stroma and have led some to speculate that definitions for medullary carcinoma are of limited value. Of all histological tumour types, medullary carcinoma, as previously defined, has the worst concordance in the EQA scheme.

(a)



(b)

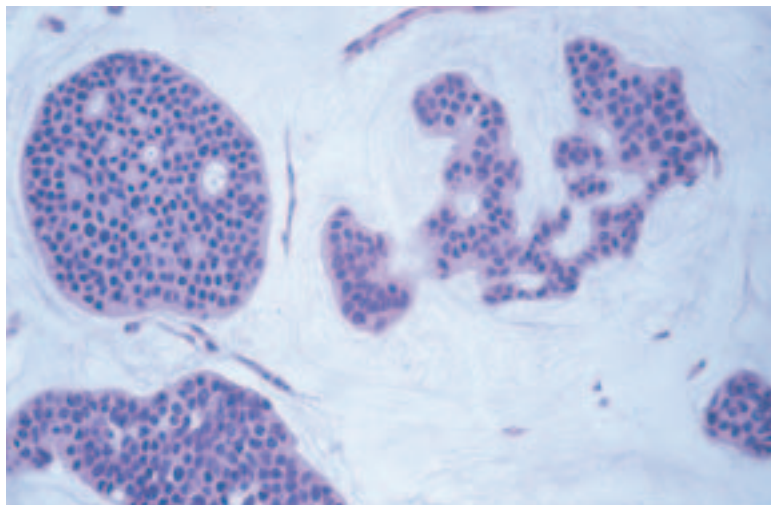


Figure 43 (a and b) An example of a mucinous carcinoma.

15.4.6 Mucinous carcinoma

This type has also been known as mucoïd, gelatinous or colloid carcinoma. There are islands of uniform small cells in lakes of extracellular mucin (Figure 43). An in situ component is uncommon. At least 90% of the tumour must exhibit the mucinous appearance to be so classified.

15.4.7 Other primary carcinoma

Other primary breast carcinomas should be entered under this heading and will include variants such as **metaplastic**, **apocrine**, **invasive micropapillary** (Figure 44) and **infiltrating papillary**.

15.5 Other malignant tumour

Non-epithelial tumours and secondary carcinomas are included in this category. For purposes of convenience, **malignant phyllodes tumours** should be recorded here.

15.6 Not assessable

This category should be ticked only if an invasive carcinoma cannot be assigned to any of the previous groups for technical reasons, eg the specimen is too small or poorly preserved.

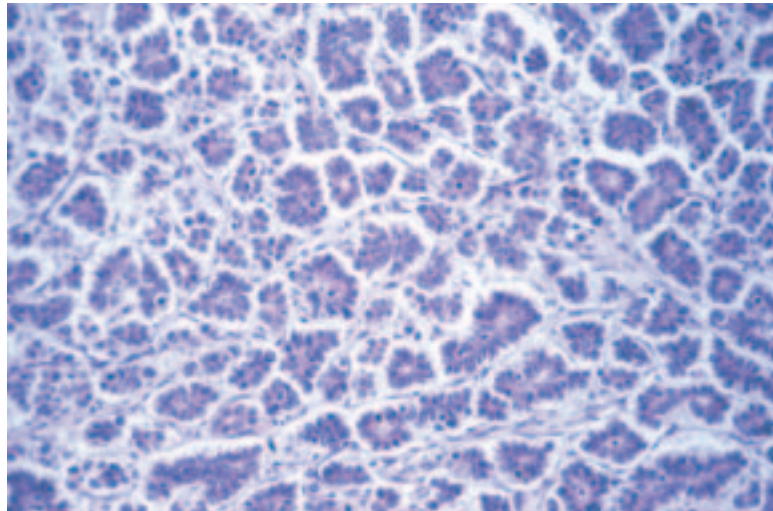


Figure 44 An example of an invasive micropapillary carcinoma.

16. TUMOUR SIZE

16.1 Invasive tumour size

The maximum dimension of any invasive tumour should be measured in the fresh or fixed state macroscopically (Figure 45). Care should be taken in the case of ovoid or stellate tumours that the largest dimension is measured and blocked, bearing in mind that this may not necessarily be the plane of initial cut into the tumour. If a specimen radiograph is available, the plane of maximum dimension can be better assessed before slicing. It is recognised that for circumscribed tumours the macroscopic measurement may be accurate if measured to the nearest millimetre, but for diffuse tumours it may be more problematic to define the precise borders of the tumour.

Blocks should also be taken to enable a measurement of the histological size of tumours. Where the maximum macroscopic diameter of a tumour can be blocked directly, it is recommended that a single block across this diameter be taken. Where a tumour is larger than can be assessed in a single block, two or more blocks are recommended from the maximum macroscopic diameter in order that the total tumour size can be estimated by adding the dimensions together or measuring the maximum dimension on the two slides fitted together. Alternatively, a large block to encompass the maximum dimension may be taken. If this is the case, at least one other normal sized tumour block should also be processed in order to allow optimal processing and to avoid the excessive use of antibodies in receptor studies. For diffuse tumours, especially diffuse lobular carcinomas, it may not be possible to macroscopically define the

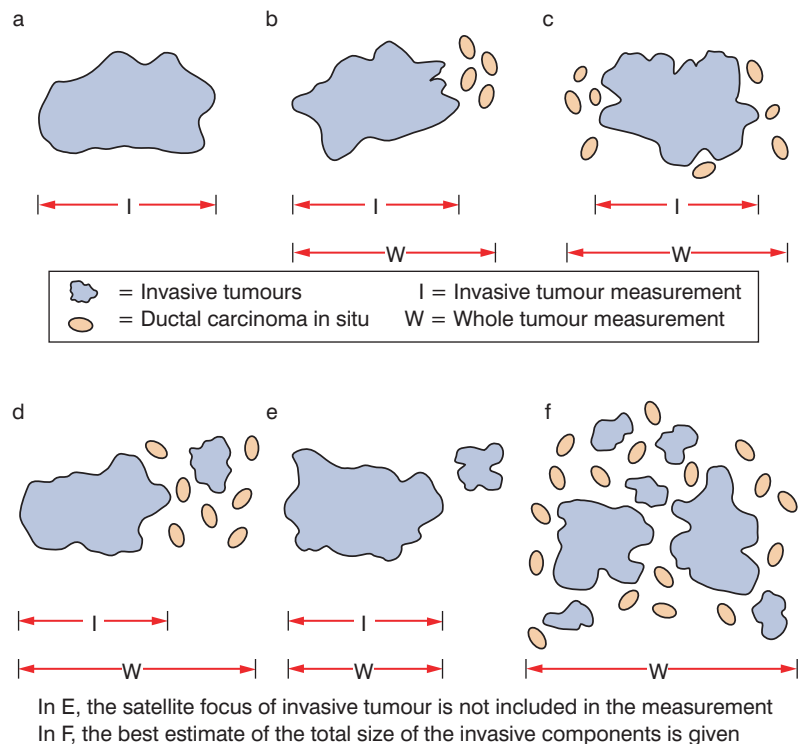


Figure 45 Measurement of carcinomas with an invasive component.

true extent of tumour and, in this case, either a large block or consecutive blocks of the whole abnormal area (including adjacent fibrotic tissue) may be necessary.

Occasionally, patients will have had a diagnostic biopsy before definitive treatment, primary chemotherapy or, exceptionally, a frozen section may have been performed. In these circumstances, tumour size may be inaccurate, but an assessment based on the ultrasound or radiographic size in conjunction with the histology may be necessary. There may also be a problem where multiple core biopsies have completely or partially removed a small tumour (see also the NHSBSP wide bore needle histology form in Appendix 2). In these situations, an estimate of the original tumour size should be given. This may need discussion with the radiologist and correlation with ultrasound or mammographic features. An estimate of the tumour size should be ascertained and a comment made under 'Comments/additional information'.

Tumour size should be measured in millimetres, and the invasive tumour size entered in the field 'Invasive tumour ...mm (largest dimension of dominant invasive tumour focus)' on the NHSBSP breast pathology data form. Satellite lesions should not be included in the measurement of the maximum invasive tumour dimension, nor should foci of vascular or lymphatic invasion (Figure 45a and b). On occasions, when foci of invasive carcinoma are close to each other within a section, it may be difficult to be certain whether they represent a main mass in continuity or whether one is a satellite focus from the other. Features that may be of assistance include the presence of normal breast parenchymal structures between the two deposits and the distance between the foci. It is impossible to strictly define a distance between the foci that can be used to decide whether one is a satellite deposit from another; if, however, the foci are 5 mm or more apart, the chances of the deposits representing one tumour appearing as separate foci as a result of plane of slicing are lower. A pragmatic approach must be taken to measurement of invasive tumour size and common sense applied when a definitive size measurement cannot be given. In addition, comparison with ultrasound or magnetic resonance imaging size may be helpful. If these are not available, mammographic size can be utilised, although it is less accurate. Finally (and least accurately), clinical size can be compared.

Where there is a discrepancy between the macroscopic size and the microscopic size, the latter should be recorded provided it is certain that the true plane of maximum dimension has been included in the slide or slides. For example, an ovoid tumour 11×8×8 mm may be underestimated histologically as 8 mm if the plane of block selection is through the centre and not in the plane of the long axis.

Measurement of histological size from the tissue sections can be made using the Vernier stage micrometer. The slide should be placed at an angle on the microscope stage so that the largest dimension is determined. Other methods include inking the edges of the tumour on the slide with marker pen and then measuring the distance between the points with a ruler, or using a magnifying device applied directly over the histological slide.

16.2 In situ (DCIS) size

Lobular neoplasia is often multifocal, and measurement of the extent of this disease is unreliable, unnecessary and unhelpful. **Only DCIS should be measured.** Undoubtedly, however, the measurement of DCIS in two dimensional slides is at best an underestimate of the total size of the in situ change. The tree like branching structure of normal breast ducts means that DCIS very rarely forms a rounded mass and ramifies within the affected duct system. Of especial note is the extension of the in situ tumour into the major duct running towards the nipple.²

Large blocks can help to delineate in situ disease. The two dimensional nature of slides may not give the true extent of disease, and block taking and measurement should be correlated with the specimen radiograph. Where the size measured is less than the size on the radiograph, further blocks should be taken to identify the limit of the calcification seen on radiography.

The measurement of the size of DCIS should be recorded on the NHSBSP reporting form in the field under non-invasive tumour 'Size (ductal only)', **not** in the whole tumour size field under invasive carcinoma.

16.3 Whole tumour size

There is no internationally recognised definition of extensive in situ carcinoma, but it has been reported that, on excision of an invasive carcinoma with a small margin of normal tissue, surrounding extensive in situ carcinoma is associated with increased risk of local recurrence. Where more extensive excision is performed, however, the significance of this factor is markedly reduced. This problem relates to adequate excision of tumour with associated in situ component and is considered to be the same problem as evaluating complete excision of pure DCIS.

The invasive tumour should be measured, as above, but the assessment of the whole tumour size including in situ carcinoma presents the same problems as in the previous section (see Figure 45). The measurement of DCIS associated with invasive carcinoma should be recorded in the whole tumour size field on the reporting form, including tumours which are predominantly composed of DCIS but have multiple foci of invasion. Measurement of the invasive component in this latter case can be problematic as in Figure 45f, where the best estimate of the invasive tumour burden should be given as the size of the tumour field. It is recommended that pathologists take blocks from macroscopically normal tissue between an excised tumour and the excision margins in all three planes of section. Slice specimen radiography may help in this assessment.

16.4 Tumour extent

If a tumour is insufficiently delineated to be measured accurately, a comment should be made under 'Comments/additional information' on the reporting form.

The fields for tumour extent on the form have been a source of confusion in the past owing to debates about the definition of multicentric or multifocal. The fields are hence now given as 'Localised' or 'Multiple invasive foci'. The field is present to record the presence or absence of multiple foci of invasive tumour within the specimen, clearly separate from each other and not connected by associated DCIS.

It is not intended that a tumour with multiple areas of invasion from extensive DCIS should be classified as multiple.

It should be noted that DCIS is a unifocal disease, although it may be extensive.^{1,14}

The designation of multiple foci should be reserved for multiple **separate** areas of invasive tumour, such as that which occurs with lobular carcinoma or tumours with extensive vascular invasion where there are multiple areas of invasive tumour as a result of extravasation of tumour cells from lymphatics and establishment of separate satellite invasive tumour foci. As noted in section 16.1, it can be difficult, if not impossible, on rare occasions to determine whether two adjacent foci represent satellite foci or one lesion mimicking this process owing to the plane of sectioning. A pragmatic approach is required: the presence of intervening normal tissue and increasing distance between foci are features that indicate that these are more likely to be multiple foci than a localised process.

Multiple synchronous primary tumours of different types should be categorised as multiple. It is recognised that this may be difficult to assess and so a 'Not assessable' box is included on the form for cases where there is doubt.

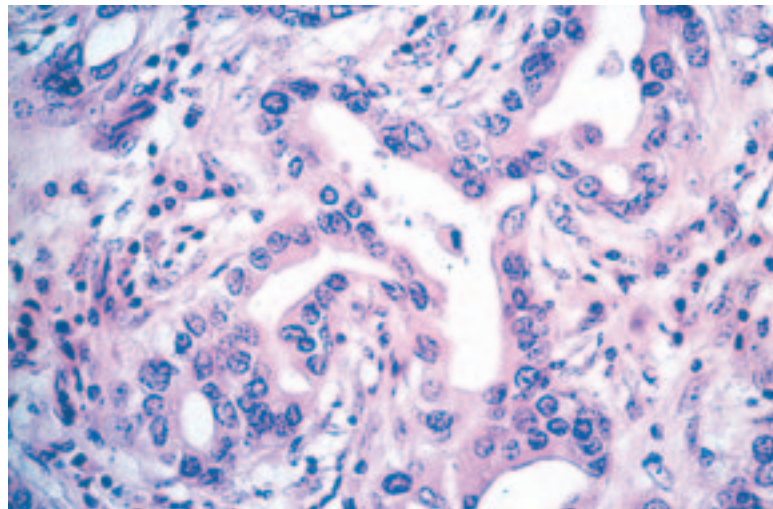
17. HISTOLOGICAL GRADE

Histological grading unequivocally provides powerful prognostic information.^{26,27} It requires some commitment and strict adherence to the accepted protocol. The method used is that described by Elston and Ellis²⁷ and involves the assessment of three components of tumour morphology: tubule/acinar/glandular formation, nuclear atypia/pleomorphism and frequency of mitoses. Each is scored from 1 to 3. Adding the scores gives the overall histological grade, as shown below.

Some degree of variation in appearance from one part of a tumour to another undoubtedly occurs; this is particularly true of tumours of mixed type.^{26,28} Assessment of tubular differentiation is made on the overall appearances of the tumour and so account is taken of any variation. Nuclear appearances are evaluated at the periphery and/or least differentiated area of the tumour to obviate differences between the growing edge and the less active centre.

Figure 46 ‘Tubule’ formation includes both formation of tubular like structure (a) and glandular acinar structures (b). Their frequency throughout the tumour area dictates assignment of the degree of tubule formation when assessing histological grade. Score 1 for tumours showing > 75% (c), score 2 for 10–75% (d) and score 3 for < 10% (e).

(a)



(b)

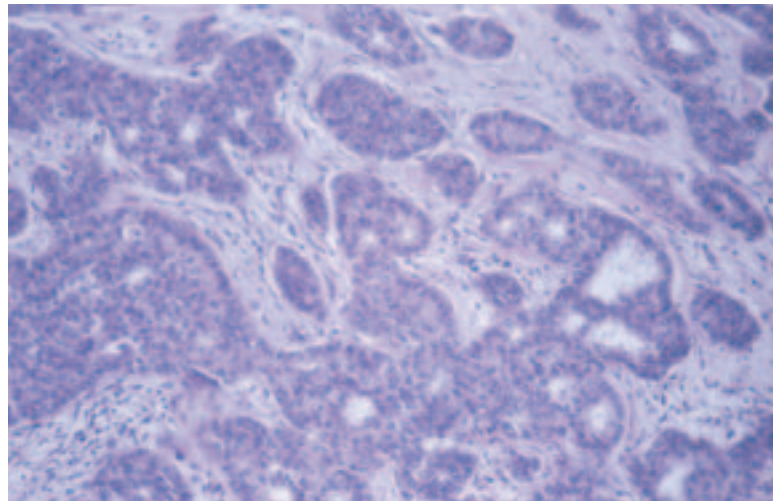
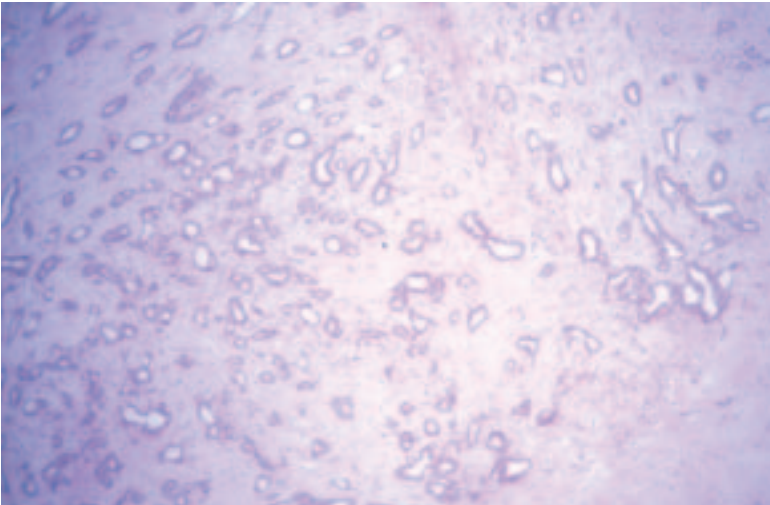
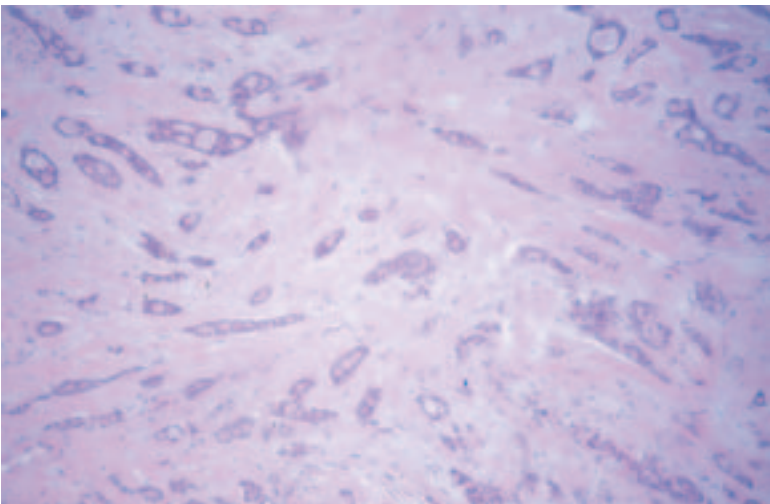


Figure 46 (a-e) Continued.

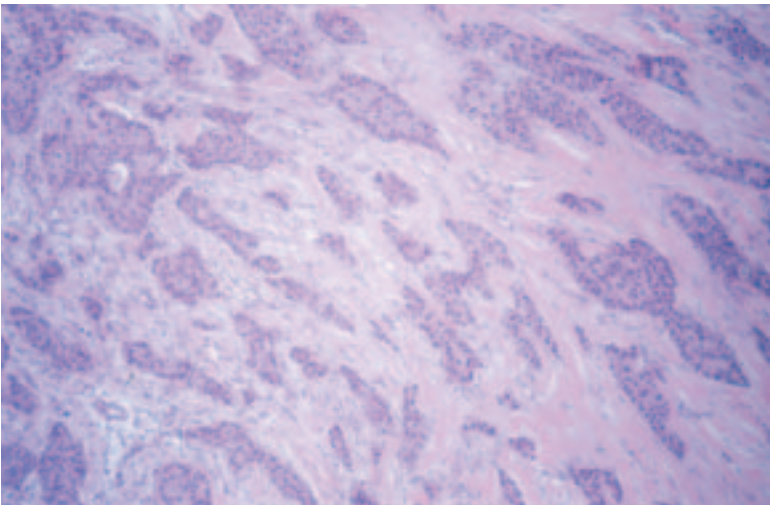
(c)



(d)



(e)



Do not expect equal numbers of cancers to fall in each grade category. Published ratios for grades 1, 2 and 3 are approximately 2:3:5 in symptomatic breast cancer,²⁶ so about half of all symptomatic cancers are grade 3. If audit of grade distribution shows substantially fewer grade 3 cases, or a majority of grade 2 cases, fixation and grading protocols should be carefully reviewed. Screen detected cancer series are likely to include a smaller proportion of high grade cases.

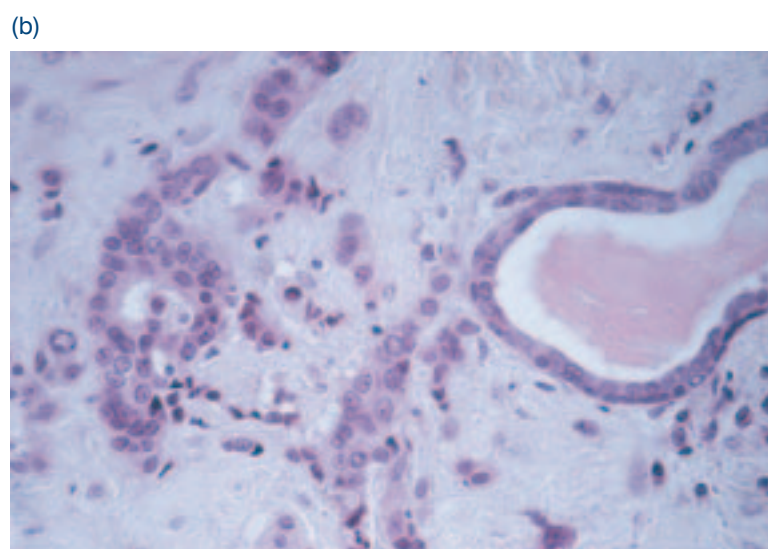
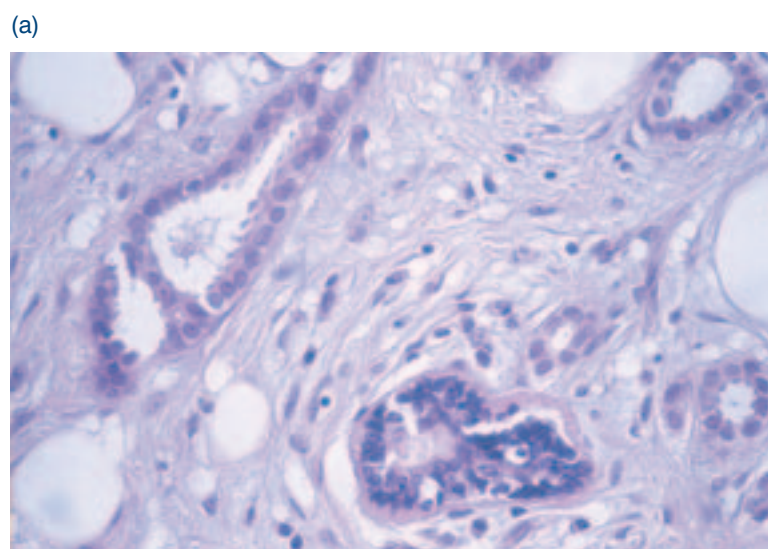
17.1 Tubule/acinar formation

All parts of the tumour are scanned and the proportion occupied by tumour islands showing clear acinar or gland formation or defined tubular structures with a central luminal space is assessed semiquantitatively (Figure 46). This assessment is generally carried out during the initial low power scan of the tumour sections.

Score

1. >75% of tumour forming tubular or glandular acinar structures.
2. 10–75% of tumour forming tubular or glandular acinar structures.
3. <10% of tumour glandular acinar structures.

Figure 47 Comparison with adjacent normal acinar or ductal epithelial cells can aid nuclear grade assignment. Small regular cells are given a score 1 (a), larger cells showing some pleomorphism score 2 (b and c). Lobular carcinoma cells usually fall into this category (c). Large cells showing marked pleomorphism are assigned to nuclear grade 3 (d).



In the assessment of tubule formation, only structures in which there are clearly defined central lumens, surrounded by polarised tumour cells, should be counted. A tumour in which 75% or more of its area is composed of such structures would score 1 point for tubule formation.

**17.2 Nuclear atypia/
pleomorphism**

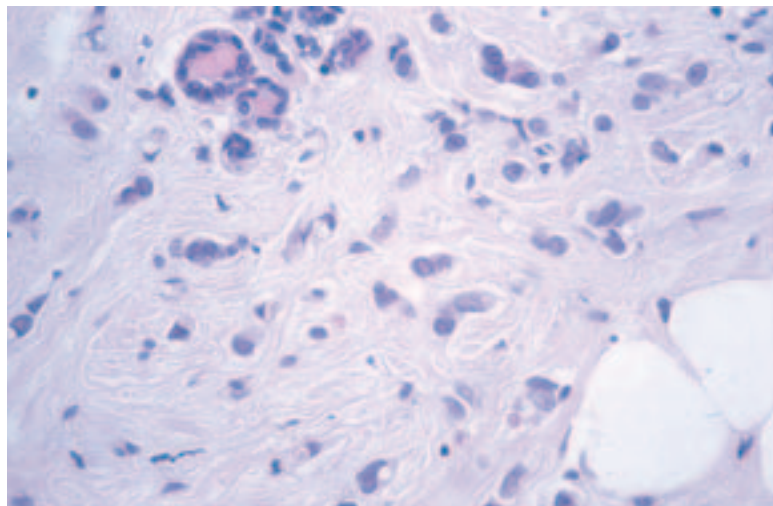
Individual pathologists differ markedly in their approach to nuclear grading, and breast specialists appear to allocate higher grades than non-specialists.²⁹ Few cancers possess the very bland nuclei warranting an atypia/pleomorphism score of 1, and obvious atypia/pleomorphism should attract a score of 3. The minimum proportion of tumour nuclei which should show marked nuclear atypia/pleomorphism before a score of 3 is allocated has not been defined, but the finding of an occasional enlarged or bizarre nucleus should not be used to give a score of 3 rather than a score of 2 (Figure 47).

Score

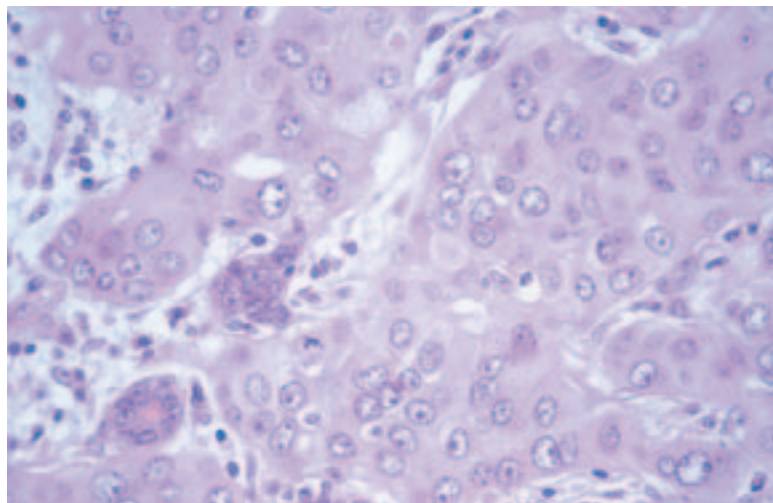
1. Nuclei small with little increase in size in comparison with normal breast epithelial cells, regular outlines, uniform nuclear chromatin, little variation in size.

Figure 47 (a–d) Continued.

(c)



(d)



2. Cells larger than normal with open vesicular nuclei, visible nucleoli and moderate variability in both size and shape.
3. Vesicular nuclei, often with prominent nucleoli, exhibiting marked variation in size and shape, occasionally with very large and bizarre forms.

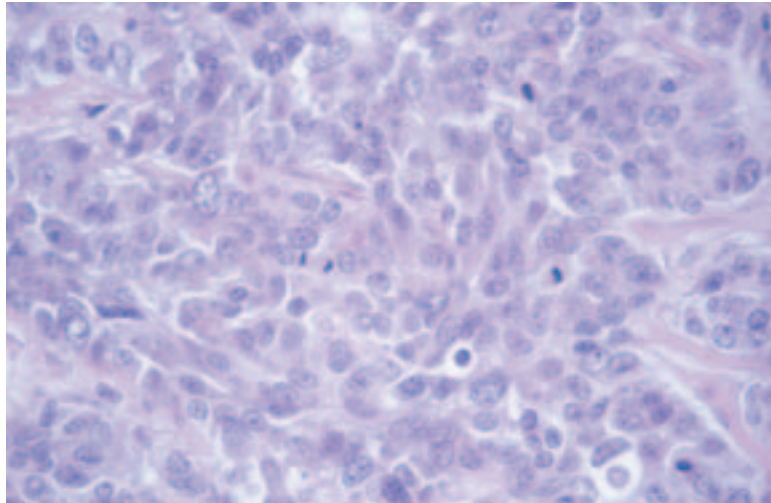
17.3 Mitoses

Accurate mitosis counting requires high quality fixation, obtained when fresh specimens are sectioned promptly, as well as tumour blocks of optimal thickness (3–4 mm) fixed immediately in neutral buffered formalin. This can be achieved without compromising the evaluation of resection margins.

17.3.1 Score

The mitosis score depends on the number of mitoses per 10 high power fields (Figure 48). The size of high power fields is very variable, so it is necessary to standardise the mitotic count using Table 4.

(a)



(b)

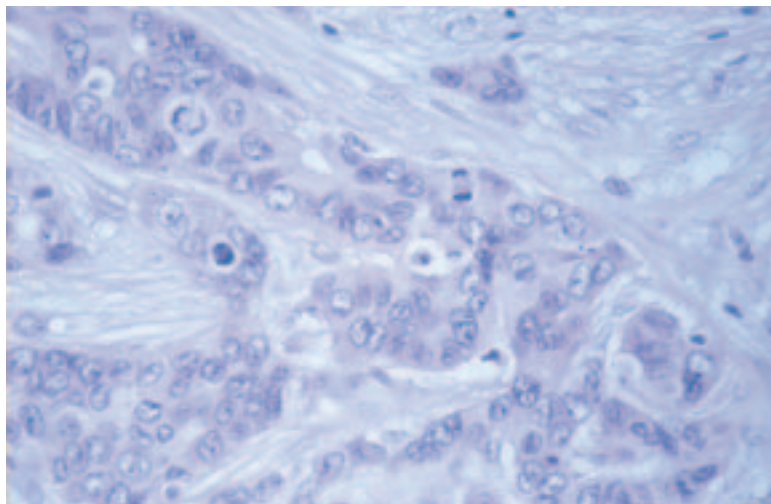


Figure 48 (a and b) Assessment of mitotic frequency requires calibration of the microscope field area to standardise mitotic grade assignment. Identification of mitoses requires optimum tissue fixation and preservation.

Pathology Reporting of Breast Disease

Table 4 Mitotic counts by field diameter corresponding to microscopic field diameter

Field diameter (mm)	Mitotic frequency score			Field diameter (mm)	Mitotic frequency score			Field diameter (mm)	Mitotic frequency score		
	1	2	3		1	2	3		1	2	3
0.40	≤4	5–9	≥10	0.50	≤7	8–14	≥15	0.60	≤10	11–20	≥21
0.41	≤4	5–9	≥10	0.51	≤7	8–14	≥15	0.61	≤10	11–21	≥22
0.42	≤5	6–10	≥11	0.52	≤7	8–15	≥16	0.62	≤11	12–22	≥23
0.43	≤5	6–10	≥11	0.53	≤8	9–16	≥17	0.63	≤11	12–22	≥23
0.44	≤5	6–11	≥12	0.54	≤8	9–16	≥17	0.64	≤11	12–23	≥24
0.45	≤5	6–11	≥12	0.55	≤8	9–17	≥18	0.65	≤12	13–24	≥25
0.46	≤6	7–12	≥13	0.56	≤8	9–17	≥18	0.66	≤12	13–24	≥25
0.47	≤6	7–12	≥13	0.57	≤9	10–18	≥19	0.67	≤12	13–25	≥26
0.48	≤6	7–13	≥14	0.58	≤9	10–19	≥20	0.68	≤13	14–26	≥27
0.49	≤6	7–13	≥14	0.59	≤9	10–19	≥20	0.69	≤13	14–27	≥28

The field diameter of the microscope should be measured using the stage graticule or a Vernier scale, and the scoring categories should be read from the corresponding line of Table 4 or Figure 49. Field diameter is a function of the objective lens and the eyepiece, so if *either* of these is changed this exercise *must* be repeated.

A minimum of 10 fields should be counted at the periphery of the tumour, where it has been demonstrated that proliferative activity is greatest.^{28,30} If there is variation in the number of mitoses in different areas of the tumour, the least differentiated area (ie with the highest mitotic count) should be assessed. If the mitotic frequency score falls very close to a score cut point, one or more further groups of 10 high power fields should be assessed to establish the correct (highest) score. It is recommended that identification of the most mitotically active or least differentiated part of the tumour forms part of the low magnification preliminary assessment of the histological section. This area should be used for mitotic count scoring. If there is no evidence of heterogeneity, mitotic scoring should be carried out at a part of the tumour periphery chosen at random. Fields chosen for scoring are selected during a random meander along the peripheral margin of the selected tumour area. Only fields with a representative tumour burden should be used. The low power scan of the tumour can be used to provide an assessment of the typical tumour to stromal ratio. Only definite mitotic figures (in any phase of the growth cycle) should be counted. Hyperchromatic nuclei and/or apoptotic nuclei should not be scored. Poor quality fixation can result in underscoring of mitotic frequency; optimal fixation is essential.

17.4 Overall grade

The use of terms such as well differentiated or poorly differentiated in the absence of a numerical grade is inappropriate. The scores for tubule formation, nuclear pleomorphism and mitoses are added together and assigned to grades, as below:

Total score of 3, 4 or 5 = Grade 1
 Total score of 6 or 7 = Grade 2
 Total score of 8 or 9 = Grade 3

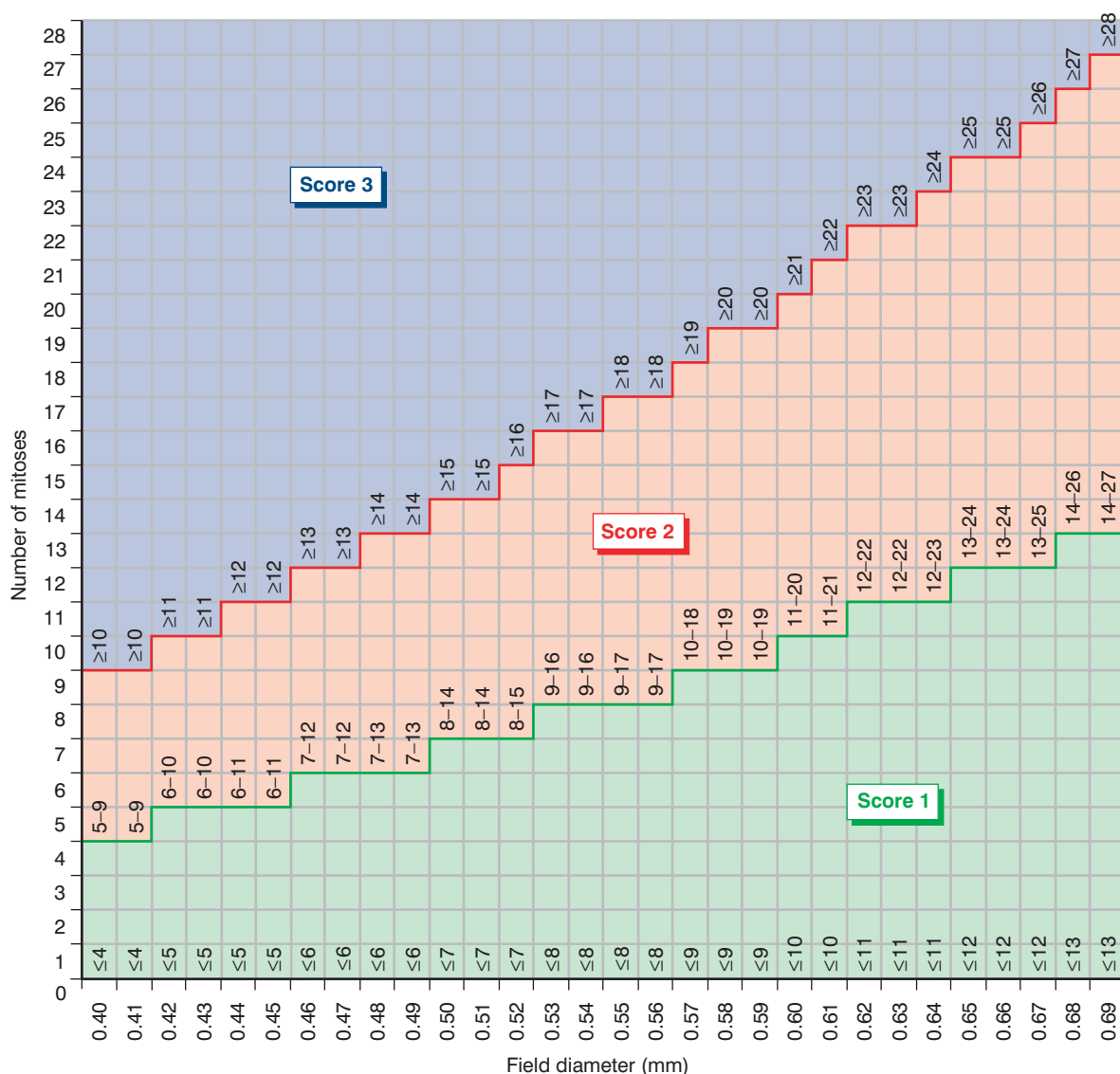


Figure 49 Aide-memoire to assist calibration of microscope field diameter with mitotic frequency count grading cut off points (see also Table 4).

It is recommended that grading is not restricted to invasive carcinoma of ductal NST but is undertaken on **all** histological subtypes. There are two major reasons for this recommendation:

- there are occasionally problems in deciding whether to classify a tumour as NST or some other subtype
- there may be significant variation in prognosis within certain subtypes, eg lobular carcinoma, and grading provides additional information.³¹

‘Not assessable’ should be ticked if for any reason the grade cannot be determined, eg specimen too poorly preserved or too small.

Grading systems other than that described above should not be used.

For audit and other purposes, it may be appropriate to record individual components of grade, including actual mitosis count and field size, which may have added prognostic significance within grade categories.³²

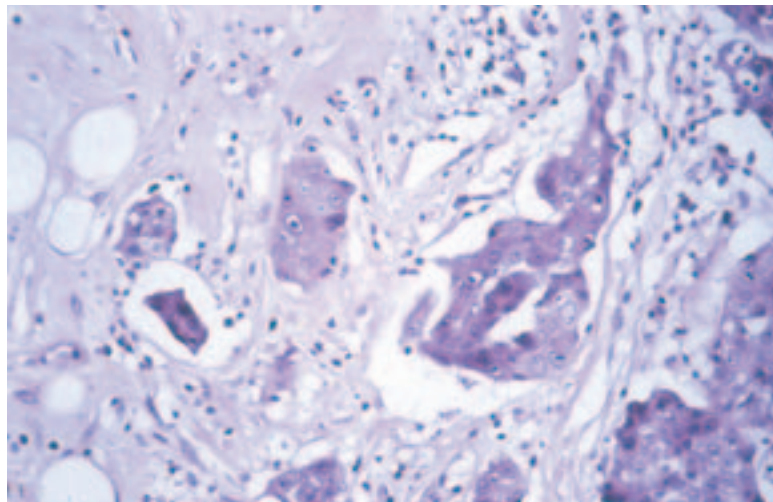
18. VASCULAR INVASION

The presence of vascular invasion is generally considered to be an adverse feature providing independent prognostic information about both local recurrence and survival.^{33,34} It is therefore important to record whether or not it is present. Because it is difficult to distinguish between lymphatic and venous channels, findings should be categorised as ‘vascular spaces’ rather than as specific channels.

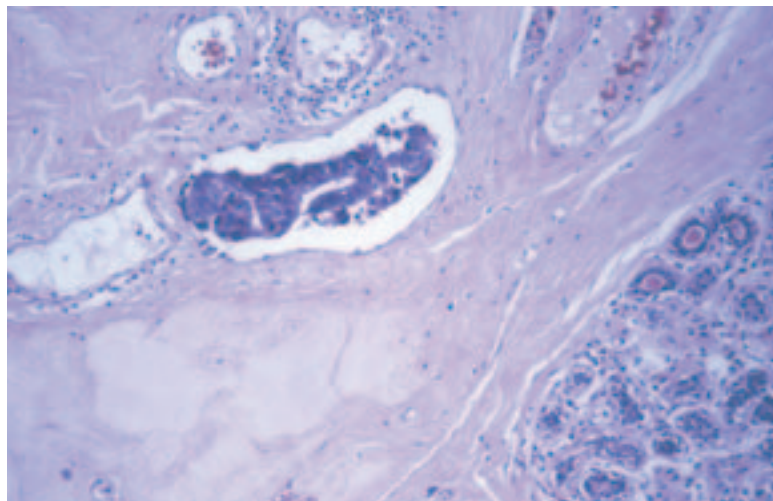
One of the major problems in trying to determine whether or not tumour cells are in a vessel is shrinkage artefact, so care should be taken, wherever possible, to ensure that there is optimal tissue fixation and processing. A clear rim of endothelium should be present before considering that a vascular space has been identified (Figure 50). The **presence** of unequivocal tumour in vascular spaces should be recorded; if there is doubt, but it is considered to be very likely, it should be recorded as **possible**; and if not present it is categorised as **not seen**. Perineural invasion should not be recorded as vascular invasion.

Figure 50 (a) Artefactual shrinkage due to poor fixation; (b) definite vascular invasion with tumour emboli in spaces with an epithelial lining.

(a)



(b)



There are various features that may be helpful in trying to identify vascular invasion and to recognise whether tumour cells are in definite vascular spaces. These are:

- groups of tumour cells in spaces around the main tumour mass; ensure that any spaces are lined by endothelial cells and are not fat spaces
- the presence of adjacent vascular channels that may be of varying sizes
- the presence within the space of erythrocytes and/or thrombus
- shrinkage artefact results in nests of cells having the shape of the space in which they lie; endothelial cells will not be seen.

The best method for assessing vascular invasion is the use of good quality, optimally fixed and processed H&E stained sections. Immunostaining for endothelial markers does not generally contribute further, but could be considered for difficult critical cases.

19. LYMPH NODE STAGE

All lymph nodes must be examined histologically, as noted in Chapter 8. Data from axillary nodes must be recorded separately from nodes from other sites.

Histological reports should include:

- the total number of lymph nodes identified
- the number of lymph nodes involved with metastatic disease
- specific axillary levels and nodes, ie the apical node, may have been identified by the surgeon and can be recorded independently, but they should also be included in the total lymph node figures
- the presence of extracapsular spread can be noted under 'Comments/additional information' but is considered to be of limited clinical value.

Although it is recognised that the evidence base for the stratification of lymph node stage is limited, adoption of the approach outlined below and described in Appendix 5 in the new TNM staging system is encouraged as it offers a pragmatic solution to the issues of classification of small metastatic deposits. It is felt appropriate for the UK and the rest of Europe to adopt this international consensus classification system in order to support an improvement in an evidence accrual based on common definitions. The system outlined below and in Appendix 5 is adapted from the TNM classification of malignant tumours.^{35,36}

19.1 Reporting and definitions of micrometastatic disease and isolated tumour cells

Micrometastasis is defined as one or more deposits of metastatic carcinoma within the lymph node that are more than 0.2 mm in size but none of which is larger than 2 mm in greatest dimension.

Cases with only isolated tumour cells (ITCs) in regional lymph nodes are classified as node negative (pN0). ITCs are single tumour cells or small clusters of cells not more than 0.2 mm in greatest dimension that are usually detected by immunohistochemistry or molecular methods but which may be verified on H&E stains. ITCs do not typically show evidence of metastatic activity (eg proliferation or stromal reaction).

20. EXCISION MARGINS

Assessment of adequacy of excision requires close correlation between the surgical excision procedure and pathological examination. In particular, it is essential that the pathologist is made aware of the depth of tissue excised and whether the surgeon has excised all the tissue from the subcutaneous to the pectoral fascia.

20.1 Invasive carcinoma

The excision margins of a well circumscribed invasive carcinoma without a significant in situ component are usually relatively simple to assess. The distance from the tumour to the nearest radial margin (medial, lateral, superior or inferior) and to the deep and superficial margins (if surgically relevant, as described in Chapter 2) should only be measured macroscopically. If the surgeon has oriented the specimen with clips or sutures, the margin assessed should be related to these. To some extent, this depends on local issues, especially where the surgeon has not excised the complete depth of breast tissue from subcutaneous to pectoral fascia. In this case, the superficial and deep margins may become relevant and should then be assessed.

The relevant margins should be painted with ink and blocks taken so that the macroscopic measurement can be confirmed microscopically. The distance from the nearest radial margin (and the anterior/subcutaneous or deep margin if involved) should be given in the 'Closest relevant margin' field on the form.

The most problematic areas of excision margin assessment are related either to diffuse tumours that are not easily visible macroscopically or to DCIS, whether alone or associated with invasive carcinoma. In the former situation, it may not be easy to define the nearest excision margin macroscopically, and a number of blocks from the nearest area of firm fatty or fibrous tissue to the margin may need to be taken. Some units employ shaved margins or large blocks in this instance and these can be very helpful, although with the former it may not be possible to give an exact distance from the margin.

20.2 DCIS and invasive carcinoma with an extensive in situ component

In the case of DCIS or invasive tumours with an extensive in situ component, it is not possible to accurately assess the distance of the in situ lesion from the nearest excision margin by the standard method of a single block taken from the tumour to the nearest excision margin such as is used for circumscribed invasive tumours. This is because of the ramifying nature of the duct system within the breast, which may contain in situ disease. Although the margin closest to the nipple is the most frequently involved margin (T. Decker, personal communication), DCIS can potentially extend to any margin of the specimen, even at some distance from the main area of calcification. There are a number of methods of assessing this problem.

Undoubtedly, large blocks are helpful for measurement of the distance of the nearest focus of in situ carcinoma from the margin. However, they can only assess margins two dimensionally, and there is a possibility of unrec-

ognised in situ tumour extending to the margin outside the plane of the large block. The previous edition of these guidelines recommended that ‘pathologists take blocks from macroscopically normal tissue between an excised tumour and margins in all three planes of section to allow comment on the extent of DCIS and its relationship to the margins’ in cases of extensive in situ carcinoma. Similarly, for pure DCIS, the previous guidelines stated that ‘the distance from the nearest excision margin should be recorded if the lesion is sufficiently delineated. If not make a comment under “Comments/additional information”. The presence of non-neoplastic breast parenchyma between the DCIS and the margin is usually associated with adequate excision.’

It now appears from the UK DCIS trial pathology review (S. Pinder, personal communication) and other studies of recurrent/residual disease post-conservation therapy that such simple rules may not be sufficient to ensure complete excision. Many units now take blocks of the major area of calcification, blocks from this area to the nearest inked margin and then take shaved margin specimens with particular reference to the nipple duct margin. The surgeon should mark this margin in cases of DCIS as, although it may be some distance from the main area of calcification, it is the most frequently involved margin and sometimes the only margin to be involved. The rationale for shaved margins is shown in Figure 4. The specimen radiograph may also be a helpful adjunct in assessing surgical clearance, although it should be borne in mind that in situ disease may be more extensive than the calcification seen mammographically, particularly for low grade disease.

See also Chapter 5.

21. STEROID RECEPTORS

21.1 Recommendations for steroid receptor testing

The steroid receptor (oestrogen and progesterone receptor) status of a breast cancer is used to determine whether or not a patient will benefit from antioestrogen treatment,³⁷ either as adjuvant therapy or for metastatic disease. Previously, assays depended on the homogenisation of fresh tumour tissue followed by ligand or antibody binding. Immunohistochemistry is now the method of choice for assessing steroid receptor status.³⁸ It has the advantage that it can be assessed on either core biopsies or therapeutic excisions, and is widely applicable. However, any laboratory undertaking immunohistochemistry must ensure that results are highly reproducible, and that they can be assessed semiquantitatively. These guidelines have been formulated to give advice.

21.2 Principles

21.2.1 Fixation

Poor fixation will affect results, particularly for oestrogen receptor. To obtain optimum fixation, it is preferable for specimens to be received as soon as possible after surgery and sliced to allow rapid and even penetration of the fixative. This should be either formal-saline or neutral buffered formalin. The rapid fixation achieved with core biopsies is a benefit.

21.2.2 Methods

1. Antigen retrieval in 0.01 M citrate buffer pH 6.0 using pressure cooking or controlled microwaving is required. The duration of antigen retrieval is critical: too short a heating time can be a major cause of poor and variable results.^{39,40}
2. Well characterised antibodies against oestrogen receptor and progesterone receptor that have been validated against other methodologies for detecting steroid receptors, eg ligand binding assays, should be used.
3. A sensitive detection method should be employed.
4. If changes are made either to the duration of antigen retrieval or to the detection system, as new reagents become available, it is important that all antibody titres are optimised to ensure clear nuclear staining with no cytoplasmic or background reactivity.
5. The optimum method for core biopsies and resection specimens may differ, and this should be taken into account when organising samples for staining.
6. Nuclear counterstaining should not obscure weak positive staining.

21.2.3 Controls

These are particularly important and must be used for each staining run. A composite block containing receptor rich, receptor poor and negative tissues should be used. Tissues to be tested should have normal breast tissue present wherever possible as well as cancer; this acts as a good internal positive control and is particularly important if fixation is sub-optimal. Negative controls should always be included. If there are any problems with the standard control or with the staining of internal normal tissue, staining should be repeated. The type and grade of the carcinoma should also be taken into account because better differentiated cases are highly unlikely to be negative.

21.3 Scoring

There are several different scoring systems^{38,41} in place. Only nuclear staining is considered, and all of the invasive component should be assessed. In order to ensure uniformity between different laboratories, we recommend that the **quick (Allred) score** is used. This is based on assessment of the proportion and intensity of staining:

Score for proportion

0=no staining
1=<1% nuclei staining
2=1–10% nuclei staining
3=11–33% nuclei staining
4=34–66% nuclei staining
5=67–100% nuclei staining

Score for intensity

0=no staining
1=weak staining
2=moderate staining
3=strong staining

The scores are summed to give a maximum of 8.

There are several reasons for evaluating the extent of reactivity of a carcinoma:

1. many of the data relate to treatment of metastatic disease, in which it has been shown that the higher the level of receptor then the greater the chance of response to endocrine therapy
2. patients whose carcinomas have no evidence of staining essentially have no chance of responding to endocrine treatment
3. determination of progesterone receptor as well as oestrogen receptor can be of value, eg for those patients whose tumour has low oestrogen receptor/high progesterone receptor values, endocrine treatment is worthwhile
4. patients whose breast cancers have very low levels of staining (quick score of 2) may benefit from adjuvant endocrine treatment.³⁸ This emphasises the need to have sensitive, reproducible techniques that can detect these very low levels.

Because most published data have come from response in metastatic disease, it is difficult to define cut off points that are applicable to the adjuvant setting, but these data will become available.

21.4 Ductal carcinoma in situ

Trials are being introduced to determine the value of endocrine therapy in ductal carcinoma in situ (DCIS), and a requirement for entry will be knowledge of the oestrogen receptor status. Currently, there is no scoring system as for invasive disease, but a cut off point of >10% cells staining has been used for defining positive in the NSABP B24 Trial.⁴² For purposes of the IBIS II trial and DCIS II trials a lower cut point has been chosen of <5%. Until further evidence becomes available the cut point of <5% should be used.

Hormone receptor status should be recorded on the NHSBSP and minimum dataset forms as positive or negative with the result of the 'quick score'.

21.5 Testing predictive factors

Updated recommendations for HER2 testing are given in Appendix 6. Guidance on quality assurance for hormone receptor testing and HER2 testing is given in Appendices 7 and 8 respectively.

22. COMMENTS/ADDITIONAL INFORMATION

Any relevant information should be entered here as free text. Please also state whether any further special investigations have been undertaken, such as hormone receptor assessment or oncogene analysis.

Many centres now use combinations of prognostic factors in the form of a prognostic index to assist clinical management. Guidance on the Nottingham Prognostic Index is given in Appendix 9.

23. FINAL HISTOLOGICAL DIAGNOSIS

If normal, tick the box and do not complete the remainder of the form. 'Normal' includes minimal alterations such as fibrosis and microscopic dilatation of acini or ducts, lobular involution and enlargement and blunt duct adenosis.

If malignant and benign changes are found, tick only the 'malignant' box. Tick the 'benign' box when the breast is neither normal nor exhibits malignancy.

24. SNOMED CODING

An aide-memoire for SNOMED coding is given in Appendix 10.

REFERENCES

1. Holland R, Hendriks JHCL, Vebeek ALM et al. Extent, distribution, and mammographic/histological correlations of breast ductal carcinoma in situ. *Lancet*, 1990, 335: 519–522.
2. Thomson JZ, Evans AJ, Pinder SE et al. Growth pattern of ductal carcinoma in situ (DCIS): a retrospective analysis based on mammographic findings. *British Journal of Cancer*, 2001, 85: 225–227.
3. Bocker W, Decker T, Ruhnke M, Schneider W. Ductal hyperplasia and ductal carcinoma in situ. *Pathologe*, 1997, 18: 3–18.
4. Fraser JL, Raza S, Chorny K et al. Columnar alteration with prominent apical snouts and secretions: a spectrum of changes frequently present in breast biopsies performed for microcalcifications. *American Journal of Surgery and Pathology*, 1998, 22: 1521–1527.
5. Schnitt SJ, Vincent-Salomon A. Columnar cell lesions of the breast. *Advances in Anatomic Pathology*, 2003, 10: 113–124.
6. Rosen PP. Columnar cell hyperplasia is associated with lobular carcinoma in situ and tubular carcinoma. *American Journal of Surgery and Pathology*, 1999, 23: 1561.
7. Page DL. Atypical hyperplasia, narrowly and broadly defined. *Human Pathology*, 1991, 22: 631–632.
8. Page DL, Dupont WD. Anatomic markers of human premalignancy and risk of breast cancer. *Cancer*, 1990, 66: 1326–1335.
9. Page DL, Dupont WD, Rogers LW, Rados MS. Atypical hyperplastic lesions of the female breast. A long-term follow-up study. *Cancer*, 1985, 55: 2698–2708.
10. Jensen RA, Dupont WD, Page DL. Diagnostic criteria and cancer risk of proliferative breast lesions. *Journal of Cellular Biochemistry*, 1993, 17 (Suppl.): 59–64.
11. Page DL, Dupont WD, Rogers LW. Ductal involvement by cells of atypical lobular hyperplasia in the breast: a long-term follow-up study of cancer risk. *Human Pathology*, 1988, 19: 201–207.
12. Marshall LM, Hunter DJ, Connolly JL et al. Risk of breast cancer associated with atypical hyperplasia of lobular and ductal types. *Cancer Epidemiology Biomarkers & Prevention*, 1997, 6: 297–301.
13. Page DL, Kidd Jr T, Dupont WD et al. Lobular neoplasia of the breast: higher risk for subsequent invasive cancer predicted by more extensive disease. *Human Pathology*, 1991, 22: 1232–1239.
14. Holland R, Hendriks JHC. Microcalcifications associated with ductal carcinoma in-situ: mammographic–pathological correlation. *Seminars in Diagnostic Pathology*, 1994, 11: 181–192.
15. Holland R, Peterse JL, Millis RR et al. Ductal carcinoma in-situ: a proposal for a new classification. *Seminars in Diagnostic Pathology*, 1994, 11: 167–180.
16. Silverstein MJ, Poller DN, Waisman JR et al. Prognostic classification of breast ductal carcinoma-in-situ. *Lancet*, 1995, 345: 1154–1157.
17. Lagios MD. Duct carcinoma in situ: pathology and treatment. *Surgical Clinics of North America*, 1990, 70: 853–871.
18. Tavassoli FA, Norris HJ. Intraductal apocrine carcinoma: a clinicopathologic study of 37 cases. *Modern Pathology*, 1994, 7: 813–818.
19. O'Malley FP, Page DL, Nelson EH, Dupont WD. Ductal carcinoma in situ of the breast with apocrine cytology: definition of a borderline category. *Human Pathology*, 1994, 25: 164–168.
20. Carter D, Orr SL, Merino MJ. Intracystic papillary carcinoma of the breast. After mastectomy, radiotherapy or excisional biopsy alone. *Cancer*, 1983, 52: 14–19.
21. Fisher ER, Brown R. Intraductal signet ring carcinoma: a hitherto undescribed form of intraductal carcinoma of the breast. *Cancer*, 1985, 55: 2533–2537.

22. Guerry P, Erlandson RA, Rosen PP. Cystic hypersecretory hyperplasia and cystic hypersecretory duct carcinoma of the breast. Pathology, therapy, and follow-up of 39 patients. *Cancer*, 1988, 61: 1611–1620.
23. *External Quality Assessment Scheme for Breast Screening Histopathology*. NHS Breast Screening Programme, 2003 (NHSBSP Publication No 57).
24. Fisher ER, Kenny JP, Sass R et al. Medullary carcinoma of the breast revisited. *Breast Cancer Research and Treatment*, 1990, 16: 215–229.
25. Ridolfi RL, Rosen PP, Port A et al. Medullary carcinoma of the breast – a clinicopathological study with a ten-year follow up. *Cancer*, 1977; 40: 1365–1385.
26. Elston CW, Ellis IO. Pathological prognostic factors in breast cancer. I. The value of histological grade in breast cancer: experience from a large study with long-term follow-up. *Histopathology*, 1991, 19: 403–410.
27. Page DL, Ellis IO, Elston CW. Histologic grading of breast cancer. Let's do it. *American Journal of Clinical Pathology*, 1995, 103: 123–124.
28. Connor AJM, Pinder SE, Elston CW et al. Intratumoural heterogeneity of proliferation in invasive breast carcinoma evaluated with MIB1 antibody. *The Breast*, 1997, 6: 171–176.
29. Dunne B, Going JJ. Scoring nuclear pleomorphism in breast cancer. *Histopathology*, 2001, 39: 259–265.
30. Verhoeven D, Bourgeois N, Derde MP et al. Comparison of cell growth in different parts of breast cancers. *Histopathology*, 1990; 17: 505–509.
31. Pereira H, Pinder SE, Sibbering DM et al. Pathological prognostic factors in breast cancer. IV. Should you be a typer or a grader? A comparative study of two histological prognostic features in operable breast carcinoma. *Histopathology*, 1995, 27: 219–226.
32. Lynch J, Pattekar R, Barnes DM et al. Mitotic counts provide additional prognostic information in grade II mammary carcinoma. *Journal of Pathology*, 2002, 196: 275–279.
33. Pinder SE, Ellis IO, Galea M et al. Pathological prognostic factors in breast cancer. III. Vascular invasion: relationship with recurrence and survival in a large series with long-term follow-up. *Histopathology*, 1994, 24: 41–47.
34. Voogd AC, Nielsen M, Peterse JL et al. Danish Breast Cancer Cooperative Group. Breast Cancer Cooperative Group of the European Organization for Research and Treatment of Cancer. Differences in risk factors for local and distant recurrence after breast-conserving therapy or mastectomy for stage I and II breast cancer, pooled results of two large European randomized trials. *Journal of Clinical Oncology*, 2001, 19: 1688–1697.
35. International Union Against Cancer (UICC). *TNM Classification of Malignant Tumors*, 6th edn. New York: Wiley, 2002.
36. American Joint Committee on Cancer (AJCC). *Cancer Staging Manual*, 6th edn. New York: Springer, 2002.
37. Early Breast Cancer Trialists' Collaborative Group. Tamoxifen for early breast cancer: an overview of randomised trials. *Lancet*, 1998, 351: 1451–1467.
38. Harvey JM, Clark GM, Osborne CK, Allred DC. Estrogen receptor status by immunohistochemistry is superior to the ligand-binding assay for predicting response to adjuvant endocrine therapy in breast cancer. *Journal of Clinical Oncology*, 1999, 17: 1474–1485.
39. Barnes DM, Millis RR, Beex LVAAM et al. Increased use of immunohistochemistry for oestrogen receptor measurement in mammary carcinoma: the need for quality assurance. *European Journal of Cancer*, 1998, 34: 1677–1682.
40. Rhodes A, Jasani B, Balaton AJ et al. Study of interlaboratory reliability and reproducibility of estrogen and progesterone receptor assays in Europe. *American Journal of Clinical Pathology*, 2001, 115: 44–58.

41. Leake R, Barnes D, Pinder S et al. Immunohistochemical detection of steroid receptors in breast cancer: a working protocol. *Journal of Clinical Pathology*, 2000, 53: 634–635.
42. Vogel VG, Costantino JP, Wickeham DL, Cronin WM. National surgical adjuvant breast and bowel project update: prevention trials and endocrine therapy of ductal carcinoma in situ. *Clinical Cancer Research*, 2003, 9: 495S–501S.

APPENDICES

APPENDIX 1:	UPDATED RCPATH GUIDELINES ON WORKLOAD FOR BREAST PATHOLOGY	97
APPENDIX 2:	WIDE BORE NEEDLE BIOPSY FORM	99
APPENDIX 3:	SYNOPTIC REPORTS	103
APPENDIX 4:	INDEX FOR SCREENING OFFICE PATHOLOGY SYSTEM	109
APPENDIX 5:	TNM CLASSIFICATION OF TUMOURS OF THE BREAST	114
APPENDIX 6:	UPDATED RECOMMENDATIONS FOR HER2 TESTING IN THE UK	118
APPENDIX 7:	QUALITY ASSURANCE FOR OESTROGEN RECEPTORS AND PROGESTERONE RECEPTORS	127
APPENDIX 8:	QUALITY ASSURANCE FOR HUMAN EPIDERMAL GROWTH FACTOR RECEPTOR 2 (HER2) IMMUNOHISTOCHEMICAL ASSAYS	129
APPENDIX 9:	NOTTINGHAM PROGNOSTIC INDEX	131
APPENDIX 10:	SUGGESTED SNOMED CODES FOR BREAST PATHOLOGY	132

APPENDIX 1: UPDATED RCPATH GUIDELINES ON WORKLOAD FOR BREAST PATHOLOGY

Micro	Macro			Very high (=10)
	Low (=1)	Intermediate (=3)	High (=5)	
Low (=1)				
Intermediate (=3)	Excision mastectomy scar (reconstruction) Breast core biopsy Excision benign breast lesion Nipple biopsy Microdochectomy	Implant capsule examination Reduction mammoplasty (unilateral or bilateral) Isolated axillary node dissection Excision benign breast lesion requiring 3-D orientation Re-excision of breast tumour without axillary node dissection	Prophylactic mastectomy	
High (=5)	Sentinel lymph node biopsy Breast core biopsy with four or more levels and/or immunohistochemistry Mammotome biopsy specimens	Excision biopsy malignant breast lesion	Excision biopsy malignant lesion requiring 3-D orientation Biopsy/excision non-palpable microcalcific lesions Wide local excision malignant lesion with axillary node dissection Mastectomy specimen Local resection for DCIS requiring 3-D orientation	
Very high (=10)				More complex cases, eg requiring radiograph of blocks/slices, repeated block selection sessions or multipart mammographically localised malignancy with specimen radiographs and separate marginal samples

Notes

Breast malignancies received fresh and cut or sampled prior to fixation and subsequent cut-up should have an additional 2 points of macroscopic time. With the exception of reduction mammoplasties for bilateral surgery, score each side separately.

**APPENDIX 2: WIDE BORE NEEDLE
BIOPSY FORM**

NHSBSP WIDE BORE NEEDLE BIOPSY FORM

Surname Forenames Date of birth
 Screening no Hospital no NHS no
 Date performed Location Operator Centre
 Kv Total exposures Total films
 Projection Marker Localisation type

Side Right Left
 Quadrant UOQ LOQ
 UIQ LIQ
 RA AXL

Number of cores

Specimen type WBN Vacuum assisted *excision* biopsy
 Vacuum assisted *diagnostic* biopsy Vacuum assisted biopsy – not further specified

Calcification present on specimen x-ray? Yes No Radiograph not seen

Comment

.....

Date reported Pathologist Report number.....

Histological opinion B1 Unsatisfactory/normal tissue only
 B2 Benign
 B3 Uncertain malignant potential
 B4 Suspicious
 B5 Malignant Malignant type in situ
 invasive
 not assessable

Histological calcification Absent Benign Malignant Both

OPTIONAL FURTHER INFORMATION

Benign lesion

Complex sclerosing lesion/radial scar Fibroadenoma Multiple papilloma
 Periductal mastitis/duct ectasia Fibrocystic change Solitary papilloma
 Sclerosing adenosis Solitary cyst Columnar cell change
 Other (please specify)

Epithelial proliferation

Not present Present without atypia Present with atypia (ductal) Present with atypia (lobular)

Malignant lesion

In situ carcinoma Not present Ductal Lobular
 DCIS grade High Intermediate Low Not assessable

Invasive carcinoma Not present

Size invasive tumourmm (largest dimension, if available)

Type No special type (ductal NST)
 Pure special type (90% purity specify components present below):
 Mixed tumour type (50–90% special type component, specify components present below):
 Other malignant tumour (please specify)

Specify type component(s) present for pure special type and mixed tumour types:

- Tubular/cribriform Lobular Mucinous Medullary/atypical medullary
 Ductal/no special type Other (please specify)

Invasive grade 1 2 3 Not assessable

Oestrogen receptor status Positive Negative Quick (Allred) score
 Not performed

Optional additional fields

Progesterone receptor status Positive Negative Quick (Allred) score
 Not performed

HER 2 status Positive Negative Score
 Not performed

APPENDIX 3: SYNOPTIC REPORTS

The use of synoptic reports is helpful, as these may act as an aide-memoire for a complete dataset. An **example** format is shown on the next page. Alternatively, adaptations of the NHSBSP or The Royal College of Pathologists' minimum dataset forms can be used.

BREAST HISTOPATHOLOGY SYNOPTIC REPORT

Name Histology number

Part 1: Macroscopy

Date received Side Left Right

Specimen type

- Diagnostic marker
- Therapeutic marker
- Wide local excision
- Simple mastectomy
- Subcutaneous/skin-sparing mastectomy
- Radical mastectomy
- Re-excision
- Other

Specimen radiograph provided Yes No

Radiological abnormality seen Yes No Unsure

R grade 1 2 3 4 5

Radiological lesion Stellate lesion Calcification Other
 Circumscribed mass Parenchymal deformity

Histological calcification present Benign Malignant Benign and malignant Absent

Specimen weight g

Ellipse of skin × mm

Nipple Normal Indrawn Not assessable

Fibrofatty tissue × × mm

Lesion measures × × mm

Site OUQ OLQ IUQ ILQ Retroareolar Not known

Macroscopic distance to nearest (.....) margin

Comments

Part 2: Invasive carcinoma

Invasive tumour size mm

Whole tumour (DCIS + invasive) size mm

Grade 1 2 3 N/A

T 1 2 3 N/A

P 1 2 3 N/A

M 1 2 3 N/A

Tumour extent Localised Multiple, evasive foci

Type No special type (ductal NST)
 Pure special type (90% purity, specify components present below)
 Mixed tumour type (50–90% special type component, specify components present below)
 Other malignant tumour (please specify)

Specify type component(s) present for pure special type and mixed tumour types:

Tubular/cribriform Lobular Mucinous Medullary like Ductal/no special type
 Other (please specify)

Vascular invasion Not seen Present Possible

Associated DCIS None Minimal (< 1 mm beyond) Extensive

DCIS grade Low Intermediate High

In situ lobular neoplasia present Yes No

Paget's disease present Yes No

Excision

Invasive tumour reaches margin Yes No Not assessable

Closest relevant margin(s) to invasive tumour; mm distant

Excision comments

Stage 1 2 3 Not assessable Lymph nodes sampled Yes No

Axillary nodes present: No Yes Total number Number positive

For single node positivity, specify Metastasis (> 2 mm)
 Micrometastasis (≤2mm to > 0.2mm)
 Isolated tumour cells (≤0.2mm)

Other nodes present No Yes Total number Number positive

Site of other nodes

Stage comments

Nottingham prognostic index

Oestrogen receptor status Positive Negative

% cells positive Quickscore/H Score

Additional comments

SNOMED Breast T04 M.....; T04 M.....
 Lymph node T08 Node negative M00100 Node positive M81406

Pathologist's signature and date

Part 5: Separate axillary staging procedure (clearance, sampling or sentinel node)

Stage 1 2 3 TNM (if used)

Axillary nodes present: No Yes Total number Number positive

For single node positivity, specify Metastasis (> 2mm)
 Micrometastasis (≤2mm to > 0.2mm)
 Isolated tumour cells (≤0.2mm)

Other nodes present No Yes Total number Number positive

Site of other nodes

Comments

SNOMED T08 Node negative M00100 Node positive M81406

Pathologist's signature and date

APPENDIX 4: INDEX FOR SCREENING OFFICE PATHOLOGY SYSTEM

Term	Place to classify on form
Abscess	Other benign pathology (specify)
Adenocarcinoma (no special type)	Invasive ductal NST
Adenoid cystic carcinoma	Other primary carcinoma (specify)
Adenoma, apocrine	Other benign pathology (specify)
Adenoma intraduct	Enter as papilloma
Adenoma of nipple	Other benign pathology (specify)
Adenoma, pleomorphic	Other benign pathology (specify)
Adenoma, tubular	Fibroadenoma
Adenomyoepithelioma	Other primary carcinoma (specify)
	OR
	Other benign pathology (specify)
Adenosis, NOS	Histology normal
Adenosis, apocrine	Other benign pathology (specify)
Adenosis, apocrine (atypical)	Other benign pathology (specify)
Adenosis, blunt duct	Columnar cell change
Adenosis, microglandular	Other benign pathology (specify)
Adenosis, sclerosing with atypia	Sclerosing adenosis with epithelial proliferation, atypia (ductal or lobular)
Adnexal tumours	Other benign pathology (specify)
Alveolar variant of lobular carcinoma	Invasive lobular
Aneurysm	Other benign pathology (specify)
Angiosarcoma	Other malignant tumour (specify)
Apocrine adenoma	Other benign pathology (specify)
Apocrine adenosis	Other benign pathology (specify)
Apocrine carcinoma (in situ)	Non-invasive malignant, ductal (specify)
Apocrine carcinoma (invasive)	Other primary carcinoma (if pure) or ductal NST
Apocrine metaplasia (multilayered/papillary)	Fibrocystic change with epithelial proliferation present without atypia
Argyrophil carcinoma	Other primary carcinoma (specify)
Arteritis	Other benign pathology (specify)
Atypical blunt duct adenosis	Epithelial proliferation, atypia (ductal)
Atypical ductal hyperplasia	Epithelial proliferation, atypia (ductal)
Atypical epitheliosis (ductal)	Epithelial proliferation, atypia (ductal)
Atypical lobular hyperplasia	Epithelial proliferation, atypia (lobular)
B-cell lymphoma	Other malignant tumour (specify)
Benign phyllodes tumour	Other benign pathology (specify)
Blunt duct adenosis	Columnar cell change
Blunt duct adenosis (atypical)	Columnar cell change with epithelial proliferation atypia (ductal)
Breast abscess	Other benign pathology (specify)
Calcification (benign)	Calcification present, benign
Calcification (malignant)	Calcification present, malignant
Carcinoma, apocrine (in situ)	Non-invasive malignant, ductal (specify type)
Carcinoma, apocrine (invasive)	Other primary carcinoma (if pure) or ductal NST

Pathology Reporting of Breast Disease

Carcinoma, clear cell	Other primary carcinoma (specify)
Carcinoma, colloid	Invasive mucinous carcinoma
Carcinoma, comedo (in situ)	Non-invasive malignant, ductal (specify type)
Carcinoma, cribriform (in situ)	Non-invasive malignant, ductal (specify type)
Carcinoma, cribriform (invasive)	Invasive tubular or cribriform
Carcinoma, ductal (in situ)	Non-invasive malignant, ductal (specify type)
Carcinoma, lobular (in situ)	Non-invasive malignant, lobular
Carcinoma, lobular (invasive)	Invasive lobular
Carcinoma, lobular variant	Invasive lobular
Carcinoma, medullary	Invasive medullary like
Carcinoma, metastatic	Other malignant tumour (specify)
Carcinoma, mixed	Other primary carcinoma (specify)
Carcinoma, mucinous	Invasive mucinous carcinoma
Carcinoma, papillary	Other primary carcinoma (specify)
Carcinoma, signet ring	Other primary carcinoma (specify)
Carcinoma, spindle cell	Other primary carcinoma (specify)
Carcinoma, squamous	Other primary carcinoma (specify)
Carcinosarcoma	Other primary carcinoma (specify)
Cellular fibroadenoma	Fibroadenoma
Clear cell carcinoma	Other primary carcinoma (specify)
Clear cell hidradenoma	Other benign pathology (specify)
Clear cell metaplasia	Other benign pathology (specify)
Collagenous spherulosis	Other benign pathology (specify)
Columnar cell alteration	Columnar cell change
Columnar cell change	Columnar cell change
Columnar cell hyperplasia	Columnar cell change
Comedocarcinoma	Non-invasive malignant, ductal
Comedocarcinoma (invasive)	Invasive ductal NST
Complex sclerosing lesion	Complex sclerosing lesion/radial scar
Cribriform carcinoma (in situ)	Non-invasive malignant, ductal (specify type)
Cribriform carcinoma (invasive)	Invasive tubular or cribriform
Cyclical menstrual changes	Histology normal
Cyst, epidermoid	Other benign pathology (specify)
Cyst, single	Solitary cyst
Cyst, multiple	Fibrocystic change
Cystic disease	Fibrocystic change
Cystic mastopathy	Fibrocystic change
Cystic hypersecretory hyperplasia	Other benign pathology (specify)
Cystic hypersecretory carcinoma	Non-invasive malignant, ductal
Ductal carcinoma (in situ)	Non-invasive malignant, ductal
Ductal carcinoma (invasive)	Invasive ductal NST
Ductal hyperplasia (regular)	Epithelial proliferation present without atypia
Ductal hyperplasia (atypical)	Epithelial proliferation, atypia (ductal)
Duct ectasia	Periductal mastitis/duct ectasia
Duct papilloma	Papilloma, single
Dysplasia, mammary	Fibrocystic change
Eccrine tumours	Other benign pathology (specify)
Epidermoid cyst	Other benign pathology (specify)
Epitheliosis (regular)	Epithelial proliferation present without atypia
Epitheliosis (atypical)	Epithelial proliferation, atypia (ductal)

Pathology Reporting of Breast Disease

Epitheliosis (infiltrating)	Complex sclerosing lesion/radial scar
Fat necrosis	Other benign pathology (specify)
Fibroadenoma	Fibroadenoma
Fibroadenoma, giant	Fibroadenoma
Fibroadenoma, juvenile	Fibroadenoma
Fibrocystic disease	Fibrocystic change
Fibromatosis	Other benign pathology (specify)
Fistula, mamillary	Other benign pathology (specify)
Focal lactational change	Histology normal
Foreign body reaction	Other benign pathology (specify)
Galactocoele	Other benign pathology (specify)
Giant fibroadenoma	Fibroadenoma
Glycogen rich carcinoma	Other primary carcinoma (specify)
Granulomatous mastitis	Other benign pathology (specify)
Haematoma	Other benign pathology (specify)
Haemangioma	Other benign pathology (specify)
Hamartoma	Other benign pathology (specify)
Hyaline epithelial inclusions	Other benign pathology (specify)
Hyperplasia, ductal (regular)	Epithelial proliferation present without atypia
Hyperplasia, ductal (atypical)	Epithelial proliferation, atypia (ductal)
Hyperplasia, lobular (= adenosis)	Histology normal
Hyperplasia, lobular (atypical)	Epithelial proliferation, atypia (lobular)
Infarct	Other benign pathology (specify)
Inflammatory carcinoma	Specify by type (usually ductal NST)
Invasive carcinoma	Specify by type
Invasive comedocarcinoma	Invasive ductal NST
Invasive cribriform carcinoma	Invasive tubular or cribriform
Involution	Histology normal
Juvenile fibroadenoma	Fibroadenoma
Juvenile papillomatosis	Other benign pathology (specify)
Lactation	Histology normal
Lactational change, focal	Histology normal
Lipoma	Other benign pathology (specify)
Lipid rich carcinoma	Other primary carcinoma (specify)
Lobular carcinoma (in situ)	Non-invasive malignant, lobular
Lobular carcinoma (invasive)	Invasive lobular
Lobular hyperplasia (= adenosis)	Histology normal
Lobular hyperplasia (atypical)	Epithelial proliferation, atypia (lobular)
Lymphoma	Other malignant tumour (specify)
Malignant phyllodes tumour	Other malignant tumour (specify)
Mammary duct ectasia	Periductal mastitis/duct ectasia
Mamillary fistula	Other benign pathology (specify)
Mastitis, acute	Other benign pathology (specify)
Mastitis, granulomatous	Other benign pathology (specify)
Mastitis, plasma cell	Periductal mastitis/duct ectasia

Pathology Reporting of Breast Disease

Mastopathia, cystic	Fibrocystic change
Medullary carcinoma	Invasive medullary like
Menopausal changes	Histology normal
Metaplasia, apocrine (single layer)	Fibrocystic change
Metaplasia, apocrine (multilayered/papillary)	Fibrocystic change with epithelial proliferation present without atypia
Metaplasia, clear cell	Other benign pathology (specify)
Metaplasia, mucoid	Other benign pathology (specify)
Metaplasia, squamous	Other benign pathology (specify)
Metaplastic carcinoma	Other primary carcinoma (specify)
Metastatic lesion	Other malignant tumour (specify)
Microcysts	Histology normal
Microglandular adenosis	Other benign pathology (specify)
Microinvasive carcinoma	Code by in situ component and specify microinvasion present
Micropapillary change	Epithelial proliferation present
Mixed carcinoma	Other primary carcinoma (specify types)
Mondar's disease	Other benign pathology (specify)
Mucinous carcinoma	Invasive mucinous carcinoma
Mucocoele-like lesion	Other benign pathology (specify)
Mucoid metaplasia	Other benign pathology (specify)
Multiple papilloma syndrome	Papilloma, multiple
Multiple papilloma syndrome with atypia	Papilloma, multiple with epithelial proliferation atypia (ductal)
Myoepithelial hyperplasia	Other benign pathology (specify)
Necrosis, fat	Other benign pathology (specify)
Nipple adenoma	Other benign pathology (specify)
Nipple – Paget's disease	Non-invasive malignant, Paget's disease
Normal breast	Histology normal
Paget's disease of nipple	Non-invasive malignant, Paget's disease
Panniculitis	Other benign pathology (specify)
Papillary carcinoma (in situ)	Non-invasive malignant, ductal (specify type)
Papillary carcinoma (invasive)	Other primary carcinoma (specify)
Papilloma, duct	Papilloma single
Papillomatosis	Epithelial proliferation (with or without atypia)
Papillomatosis, juvenile	Other benign pathology (specify)
Papillomatosis, sclerosing	Specify under other benign pathology as adenoma of nipple
Phyllodes tumour (low grade)	Other benign pathology (specify)
Phyllodes tumour (high grade)	Other malignant tumour (specify)
Pregnancy changes	Histology normal
Radial scar	Complex sclerosing lesion/radial scar
Regular hyperplasia	Epithelial proliferation present without atypia
Sarcoidosis	Other benign pathology (specify)
Sarcoma	Other malignant tumour (specify)
Sclerosing adenosis with atypia	Sclerosing adenosis with epithelial proliferation, atypia (ductal or lobular)
Sclerosing subareolar proliferation	Specify under other benign pathology as adenoma of nipple

Pathology Reporting of Breast Disease

Squamous carcinoma
Squamous metaplasia
Spindle cell carcinoma
Scar, radial

Trauma
Tuberculosis
Tubular adenoma
Tubular carcinoma

Wegener's granulomatosis

NST, no special type; NOS, not otherwise specified.

Invasive malignant, other (specify)
Other benign pathology (specify)
Invasive malignant, other (specify)
Complex sclerosing lesion/radial scar

Other benign pathology (specify)
Other benign pathology (specify)
Fibroadenoma
Invasive tubular or cribriform

Other benign pathology (specify)

APPENDIX 5: TNM CLASSIFICATION OF TUMOURS OF THE BREAST

TNM clinical classification¹

T – Primary tumour

TX	Primary tumour cannot be assessed
T0	No evidence of primary tumour
Tis	Carcinoma in situ
Tis (DCIS)	Ductal carcinoma in situ
Tis (LCIS)	Lobular carcinoma in situ
Tis (Paget)	Paget's disease of the nipple with no tumour

Note

Paget's disease associated with a tumour is classified according to the size of the tumour.

T1	Tumour 2 cm or less in greatest dimension
T1 mic	Microinvasion 0.1 cm or less in greatest dimension*
T1a	More than 0.1 cm but not more than 0.5 cm in greatest dimension
T1b	More than 0.5 cm but not more than 1 cm in greatest dimension
T1c	More than 1 cm but not more than 2 cm in greatest dimension
T2	Tumour more than 2 cm but not more than 5 cm in greatest dimension
T3	Tumour more than 5 cm in greatest dimension
T4	Tumour of any size with direct extension to chest wall or skin only as described in T4a to T4d

Note

Chest wall includes ribs, intercostal muscles and serratus anterior muscle, but not pectoral muscle.

T4a	Extension to chest wall
T4b	Oedema (including peau d'orange), ulceration of the skin of the breast or satellite skin nodules confined to the same breast
T4c	Both 4a and 4b, above
T4d	Inflammatory carcinoma†

Notes

*Microinvasion is the extension of cancer cells beyond the basement membrane into the adjacent tissues with no focus more than 0.1 cm in greatest dimension. When there are multiple foci of microinvasion, the size of only the largest focus is used to classify the microinvasion. (Do not use the sum of all individual foci.) The presence of multiple foci of microinvasion should be noted, as it is with multiple larger invasive carcinomas.

†Inflammatory carcinoma of the breast is characterized by diffuse, brawny induration of the skin with an erysipeloid edge, usually with no underlying mass. If the skin biopsy is negative and there is no localized measurable primary cancer, the T category is pTX when pathologically staging a clinical inflammatory carcinoma (T4d). Dimpling of the skin, nipple retraction or other skin changes, except those in T4b and T4d, may occur in T1, T2 or T3 without affecting the classification.

Pathology Reporting of Breast Disease

N – Regional lymph nodes²

NX	Regional lymph nodes cannot be assessed (eg previously removed)
N0	No regional lymph node metastasis
N1	Metastasis in movable ipsilateral axillary lymph node(s)
N2	Metastasis in fixed ipsilateral axillary lymph node(s) or in clinically apparent* ipsilateral internal mammary lymph node(s) in the <i>absence</i> of clinically evident axillary lymph node metastasis
N2a	Metastasis in axillary lymph node(s) fixed to one another or to other structures
N2b	Metastasis only in clinically apparent* internal mammary lymph node(s) and in the <i>absence</i> of clinically evident axillary lymph node metastasis
N3	Metastasis in ipsilateral infraclavicular lymph node(s) with or without axillary lymph node involvement; or in clinically apparent* ipsilateral internal mammary lymph node(s) and when occurring in the <i>presence</i> of clinically evident axillary lymph node metastasis; or metastasis in ipsilateral supraclavicular lymph node(s) with or without axillary or internal mammary lymph node involvement
N3a	Metastasis in infraclavicular lymph node(s)
N3b	Metastasis in internal mammary and axillary lymph nodes
N3c	Metastasis in supraclavicular lymph node(s)

Note

*Clinically apparent, ie detected by clinical examination or by imaging studies (excluding lymphoscintigraphy)

M – Distant metastasis

MX	Distant metastasis cannot be assessed
M0	No distant metastasis
M1	Distant metastasis

pTNM pathological classification

pT – Primary tumour

The pathological classification requires the examination of the primary carcinoma with no gross tumour at the margins of resection. A case can be classified as pT if there is only microscopic tumour in a margin.

The pT categories correspond to the T categories.

Note

When classifying pT, the tumour size is a measurement of the invasive component. If there is a large in situ component (eg 4 cm) and a small invasive component (eg 0.5 cm), the tumour is coded pT1a.

pN – Regional lymph nodes³

pNX	Regional lymph nodes cannot be assessed (not removed for study or previously removed)
pN0	No regional lymph node metastasis*
pN1mi	Micrometastasis (larger than 0.2 mm, but none larger than 2 mm in greatest dimension)
pN1	Metastasis in 1–3 ipsilateral axillary lymph node(s), and/or in internal mammary nodes with microscopic metastasis detected by sentinel lymph node dissection but not clinically apparent†
pN1a	Metastasis in 1–3 axillary lymph node(s), including at least one larger than 2 mm in greatest dimension
pN1b	Metastasis in internal mammary lymph nodes with microscopic metastasis detected by sentinel lymph node dissection but not clinically apparent†
pN1c	Metastasis in 1–3 axillary lymph nodes and internal mammary lymph nodes with microscopic metastasis detected by sentinel lymph node dissection but not clinically apparent†
pN2	Metastasis in 4–9 ipsilateral axillary lymph nodes, or in clinically apparent‡ ipsilateral internal mammary lymph node(s) in the absence of axillary lymph node metastasis
pN2a	Metastasis in 4–9 axillary lymph nodes, including at least one that is larger than 2 mm
pN2b	Metastasis in clinically apparent‡ internal mammary lymph node(s), in the absence of axillary lymph node metastasis
pN3	Metastasis in 10 or more ipsilateral axillary lymph nodes; or in infraclavicular lymph nodes; or in clinically apparent‡ ipsilateral internal mammary lymph nodes in the presence of 1 or more positive axillary lymph nodes; or in more than 3 axillary lymph nodes with clinically negative, microscopic metastasis in internal mammary lymph nodes; or in ipsilateral supraclavicular lymph nodes
pN3a	Metastasis in 10 or more axillary lymph nodes (at least one larger than 2 mm) <i>or</i> metastasis in infraclavicular lymph nodes
pN3b	Metastasis in clinically apparent‡ internal mammary lymph node(s) in the presence of 1 or more positive axillary lymph node(s); or metastasis in more than 3 axillary lymph nodes and in internal mammary lymph nodes with microscopic metastasis detected by sentinel lymph node dissection but not clinically apparent†
pN3c	Metastasis in supraclavicular lymph node(s)

Notes

*Cases with only isolated tumour cells (ITCs) in regional lymph nodes are classified as pN0. ITCs are single tumour cells or small clusters of cells, not more than 0.2 mm in greatest dimension, that are usually detected by immunohistochemistry or molecular methods but which may be verified on haematoxylin and eosin (H&E) stains. ITCs do not typically show evidence of metastatic activity (eg proliferation or stromal reaction).

†Not clinically apparent, ie not detected by clinical examination or by imaging studies (excluding lymphoscintigraphy).

‡Clinically apparent, ie detected by clinical examination or by imaging studies (excluding lymphoscintigraphy) or grossly visible pathologically.

Pathology Reporting of Breast Disease

pM – Distant metastasis

The pM categories correspond to the M categories.

Stage grouping

Stage 0	Tis	N0	M0
Stage I	T1	N0	M0
Stage IIA	T0	N1	M0
	T1	N1	M0
	T2	N0	M0
Stage IIB	T2	N1	M0
	T3	N0	M0
Stage IIIA	T0	N2	M0
	T1	N2	M0
	T2	N2	M0
	T3	N1, N2	M0
Stage IIIB	T4	N0,N1,N2	M0
Stage IIIC	Any T	N3	M0
Stage IV	Any T	Any N	M1

¹Adapted with permission from Sobin LH, Wittekind C (eds). *TNM Classification of Malignant Tumors*, 6th edn. New York: Wiley, 2002.

A help desk for specific questions about the TNM classification is available at <http://tnm.uicc.org>

²The regional lymph nodes are:

1. *Axillary* (ipsilateral): interpectoral (Rotter) nodes and lymph nodes along the axillary vein and its tributaries, which may be divided into the following levels:
 - (i) *Level I* (low axilla): lymph nodes lateral to the lateral border of pectoralis minor muscle.
 - (ii) *Level II* (mid-axilla): lymph nodes between the medial and lateral borders of the pectoralis minor muscle and the interpectoral (Rotter) lymph nodes.
 - (iii) *Level III* (apical axilla): apical lymph nodes and those medial to the medial margin of the pectoralis minor muscle, including those designated as subclavicular, infraclavicular, or apical.

Note Intramammary lymph nodes are coded as axillary lymph nodes, level I.

2. *Infraclavicular (subclavicular)* (ipsilateral).
3. *Internal mammary* (ipsilateral): lymph nodes in the intercostal spaces along the edge of the sternum in the endothoracic fascia.
4. *Supraclavicular* (ipsilateral).

³The pathological N classification requires the resection and examination of at least the low axillary lymph nodes (level I). Examination of one or more sentinel lymph nodes may be used for pathological classification. If classification is based solely on sentinel node biopsy without subsequent axillary lymph node dissection, it should be designated (sn) for sentinel node, eg pN1(sn).

APPENDIX 6: UPDATED RECOMMENDATIONS FOR HER2 TESTING IN THE UK

Writing party

Dr IO Ellis (1, 3, 4), Dr J Bartlett (3, 5), Professor M Dowsett (3, 6), Dr S Humphries (1, 7), Dr B Jasani (2, 8), Mr K Miller (2, 9), Dr SE Pinder (1, 3, 4), Dr A Rhodes (2, 9) and Professor R Walker (1, 10)

Writing party affiliations

1. National Coordinating Group for Breast Screening Pathology
2. UK NEQAS for Immunocytochemistry Scheme
3. National HER2 Reference Laboratory Service
4. Department of Histopathology, Nottingham City Hospital
5. University Department of Surgery, Glasgow Royal Infirmary
6. Department of Biochemistry, Royal Marsden Hospital, London
7. Department of Cellular Pathology, Preston Hall Hospital, Maidstone
8. Department of Pathology, University of Wales College of Medicine, Cardiff
9. Department of Histopathology, University College London Medical School
10. Department of Pathology, University of Leicester

Introduction

The humanised anti-HER-2/neu (also known as c-erbB-2, further denoted HER2) monoclonal antibody trastuzumab (Herceptin)¹ has recently been endorsed by the National Institute for Clinical Excellence (NICE) for the treatment of metastatic disease² (Figure A6.1) (<http://www.nice.org.uk/article.asp?a=29280>). Establishing tumour HER2 status is a prerequisite for the use of trastuzumab.^{1,2} These guidelines update the previous UK guidelines³ and have been formulated to give advice on methodology and quality assurance for local testing to ensure that HER2 testing results are accurate and reliable, regardless of the test that is used.

General principles

Suitable samples

Formalin fixed, paraffin embedded tumour tissue samples are appropriate for assay.⁴⁻⁹ Ideally, buffered formalin should be used for fixation as use of Bouin's fixative will preclude testing by fluorescence in situ based methods. Other methods of tissue fixation can also adversely affect antigen reactivity.

Caseload

- Laboratories providing a testing service should be carrying out a minimum of 250 assays per year for immunohistochemical detection of HER2. There is evidence of higher consistency of assay quality when tests are performed by high volume reference laboratories.^{10,11} This target level has also been set to ensure continuing expertise of assay providers.
- Centres with low numbers of cases (<250 per year) requiring immunohistochemistry (IHC) assay should consider using a reference laboratory service.

The clinical effectiveness and cost effectiveness of trastuzumab therapy for the treatment of advanced breast cancer

1. Guidance
 - 1.1 Trastuzumab in combination with paclitaxel (combination trastuzumab is currently only licensed for use with paclitaxel) is recommended as an option for people with tumours expressing human epidermal growth factor receptor 2 (HER2) scored at levels of 3+ who have not received chemotherapy for metastatic breast cancer and in whom anthracycline treatment is inappropriate.
 - 1.2 Trastuzumab monotherapy is recommended as an option for people with tumours expressing HER2 scored at levels of 3+ who have received at least two chemotherapy regimens for metastatic breast cancer. Prior chemotherapy must have included at least an anthracycline and a taxane, where these treatments are appropriate. It should also have included hormonal therapy in suitable oestrogen receptor positive patients.
 - 1.3 HER2 levels should be scored using validated immunohistochemical techniques and in accordance with published guidelines. Laboratories offering tissue sample immunocytochemical or other predictive tests for therapy response should use validated standardised assay methods and participate in and demonstrate satisfactory performance in a recognised external quality assurance scheme.

Figure A6.1 NICE summary statement.

- Similar principles apply to fluorescence in situ hybridisation (FISH) testing, and it is recommended that laboratories testing < 100 cases per year consider referral of their workload to a reference laboratory. A smaller caseload has been set for FISH assay as it is generally accepted to be a more discriminant test at the positive–negative borderline, has greater ease of methodological standardisation and has less observer variation.

Appropriate laboratory assay methods

Immunohistochemistry (IHC) and fluorescence in situ hybridisation (FISH)^{5–9} are the techniques recommended for determining HER2 status. Currently, other available HER2 testing techniques (chromogenic in situ hybridisation (CISH), polymerase chain reaction, enzyme-linked immunosorbent assay, Southern blotting) should be used for research only.

For both immunohistochemical and FISH based HER2 testing, comprehensive standardisation of methodology, including monitoring of scoring procedures and the inclusion of validated controls, is mandatory. In the UK, participation and satisfactory performance in the current National External Quality Assessment Scheme for Immunocytochemistry (NEQAS) scheme for IHC and the forthcoming NEQAS scheme for HER2 FISH is a requirement. These schemes are open to laboratories across Europe. Although published data support the use of FISH for the selection of patients most likely to respond to trastuzumab, the current UK licence for this agent allows treatment of patients with tumours strongly staining by IHC. Worldwide, there remains an ongoing debate as to whether laboratories should switch to the use of FISH for all specimens, removing the need for a second tier of testing to identify HER2 positive

cases, or adopt the two tier testing strategy (Figure A6.2) currently in use in the UK reference laboratories. Current experience from the UK reference laboratories indicates that there is a very high level of correlation between IHC and FISH assay results in the 0/1+ and 3+ IHC categories, negating the need for dual IHC and FISH based assay in the majority of cases;¹² however, other published studies show higher rates of discordance. Caution may be needed before extrapolating the experience of the reference centres to laboratories with lower case loads.

While the UK licence remains focused on IHC positivity, it is logical, in the light of such data, to use FISH as a secondary test in the equivocal (2+) IHC category to clarify the HER2 status of these cases (Figure A6.2); however, once trastuzumab is licensed for both FISH and IHC positive cases it is possible that any advantage of the current two tier testing system will be scrutinised. In this case, as at present in other countries, some laboratories will choose to use FISH as a front line diagnostic test without the use of IHC. It is also expected that emerging data on the accuracy of prediction of the response to HER2 targeted therapies will influence the choice of testing method.

In summary, current UK recommendations are for a two tier testing strategy using the model shown in Figure A6.2, but this does not preclude laboratories, following licence revision, from using primary FISH testing.

Controls

The inclusion of controls and their detailed scrutiny are essential to ensure test accuracy. A recommended positive control or controls producing results close to important decision making points and a negative control are recommended.

Cell line preparations containing multiple samples of known HER2 status characterised by FISH and IHC are useful as controls.¹³ Where possible, tissue based controls, preferably from breast cancers, should also be used in all assay runs.




Figure A6.2 Recommended testing algorithm.

Excessive antigen retrieval can be monitored by an evaluation of normal breast epithelial cells as an internal control. Should membrane reactivity be identified in the normal cell population, excessive antigen retrieval may have occurred and retesting of the entire run should be considered.

Evaluation

For assessment of both IHC and FISH preparations, training and experience in interpretation of histological characteristics of breast tissue is essential. Recognition of different histological tumour types is required. In particular, HER2 status should only be determined on the invasive portion of the tumour, and IHC positivity or FISH amplification should not be reported as a positive result in isolation. Image analysis systems are currently under investigation and may provide alternatives to manual scoring for both IHC and FISH in the future. However, at present, insufficient evidence is available to recommend their routine use in the diagnostic setting.

Immunohistochemistry

For all immunohistochemistry tests

Antigen retrieval processes are critical – they must be standardised and must follow strict protocols. The antibody used and its titre should be predefined. Standardisation can be achieved using commercial assay systems such as the HercepTest (DakoCytomation). For in-house assays, no single antibody has been consistently demonstrated to be superior in terms of specificity and sensitivity. At present, antibody clones CB11 (Novocastra, Newcastle upon Tyne, UK), TAB 250 (Zymed, San Francisco, CA, USA) and polyclonal anti-sera AO485 (DakoCytomation, Ely, Cambridgeshire, UK) are the most widely used for all assay methods. Test conditions (temperature, exposure time, etc) should be standardised.

Validation of standardised assay method

Test conditions should be optimised so that distinct moderate or strong membrane staining identifies FISH positive samples. This can be achieved by:

1. dual IHC and FISH assay of a contemporary series of breast carcinomas (minimum 100 cases). Use of tumour tissue array blocks for this purpose may reduce costs. FISH assay can be confined to those cases demonstrating membrane reactivity (1, 2 or 3+)
2. the use of tumour tissue array blocks for validation may reduce costs. It may be possible to obtain such sections, which have already been scored for IHC and FISH, from a research laboratory or reference source.

Laboratories not wishing to standardise in-house methodology should consider using a commercial kit assay system such as the HercepTest (DakoCytomation).

Scoring immunohistochemistry

Only membrane staining of the invasive tumour should be considered when scoring IHC tests. If a commercial kit assay system is used, it is recommended that laboratories adhere strictly to the kit assay protocol and scoring methodology. Local modifications of techniques can lead to false positive and negative assay results. The scoring method recom-

mended is a semiquantitative system based on the intensity of reaction product and percentage of membrane positive cells, giving a score range of 0–3+ (Table A6.1). Samples scoring 3+ are regarded as unequivocally positive, and those scoring 0/1+ as negative. Borderline scores of 2+ require confirmation using another analysis system, ideally FISH (Figure A6.2).

Non-commercial kit assay methods can be scored on a similar basis or by modification to a three tier system of positive, borderline and negative. Until better evidence on scoring methodology emerges, the cut off points for such simplified assay scoring systems should be based on the existing HercepTest kit method with a positive result being based on a score of 3+, a borderline result on a score of 2+ and a negative result on a score of 1+ or 0 (Figure A6.2 and Table A6.1).

Interobserver variation in the assessment of staining can lead to misclassification of HER2 status.¹⁴ Each individual assessor should standardise scoring against known positive, negative and borderline cases. It is also preferable to assess comparability of scoring with a colleague on a regular basis.

Quality assurance

All clinical laboratories utilising assays for HER2 as predictive or prognostic tests must participate in an appropriate external quality assurance (EQA) programme such as that run by the UK National External Quality Assessment Scheme for Immunocytochemistry (UK NEQAS-ICC).

On a quarterly basis, UK NEQAS-ICC circulates to over 100 laboratories unstained sections from a formalin fixed and paraffin processed block comprising the human breast carcinoma cell lines MDA-MB-453, BT-20 and MCF-7 and the ovarian carcinoma cell line SKOV-3. Previous FISH analysis on these cell lines has shown the SKOV-3 and MDA-MB-453 cell lines to have *HER2* gene amplification, whereas the cell lines BT-20 and MCF-7 do not.¹³ With appropriate assay sensitivity, the cell line SKOV-3 stains unequivocally positive (3+), and the cell lines MCF-7 and BT-20 stain unequivocally negative (0 or 1+). The most appropriate result on the cell line MDA-MB-453 is 2+. Following strict adherence

Table A6.1 Recommended IHC scoring method

Score to report	HER2 protein overexpression assessment	Staining pattern
0	Negative	No staining is observed, or membrane staining in less than 10% of tumour cells
1+	Negative	A faint/barely perceptible membrane staining is detected in more than 10% of tumour cells. The cells are only stained in part of the membrane
2+	Borderline	A weak to moderate complete membrane staining is observed in more than 10% of tumour cells
3+	Positive	A strong complete membrane staining is observed in more than 10% of the tumour cells

to the Dako HercepTest staining protocol, it has been shown that over 80% of laboratories using the HercepTest achieve this permutation of immunostaining on the cell lines SKOV-3, MDA-MB-453, BT-20 and MCF-7. Laboratories using individually customised assays employing the clones CB11 and TAB 250 and Dako polyclonal antisera have achieved equivalent staining.

Participating laboratories are requested to test the UK NEQAS sections and their own in-house control for HER2 and to return them to the organising centre for evaluation by a panel of five expert assessors using the method of evaluation initially devised for the Herceptin Clinical Trials Assay, with the median value from the five assessors being taken as the final score.¹³⁻¹⁵

In order to identify and rectify suboptimal performance for HER2 assays by UK laboratories within an acceptable time frame, UK NEQAS-ICC will approach all UK laboratories achieving an inappropriate result on the UK NEQAS sections (a score other than 3+, 2+, 0/1+ and 0/1+ on the cell lines SKOV-3, MDA-MB-453, BT-20 and MCF-7 respectively) and provide advice for improvement. If any of these participating laboratories achieves an inappropriate result at two subsequent runs on the UK NEQAS sections following this advice, it will be issued a warning letter. With the issue of this warning letter, UK NEQAS will provide further technical advice and support. This will include attendance at the UK NEQAS organiser's laboratory by the biomedical scientist from the poorly performing laboratory. All attempts will be made to assist the laboratory to improve. Failure to do so, however, with the laboratory accruing a total of four successive inappropriate scores on the UK NEQAS sections despite intensive advice and assistance, will result in the laboratory concerned being removed from the UK NEQAS for HER2 scheme register and being reported to the chairman of the National Quality Assurance Advisory Panel (NQAAP). This may ultimately result in the laboratory concerned losing its Clinical Pathology Accreditation (UK) Ltd (CPA) status for this test. However, the laboratory will be permitted to continue participating in EQA for HER2 (if it so wishes) and the chairman of NQAAP will be notified if it is able to show significant improvement by subsequently accruing acceptable results at all of four successive assessment runs. This approach will ensure that poorly performing laboratories are identified promptly and the situation rectified through appropriate action being taken within a 12 month period, either by the laboratories showing improvement to an acceptable standard or by being removed from the UK NEQAS participation register and losing their accreditation status for this test.

Fluorescence in situ hybridisation (FISH)

FISH testing for HER2 should meet the following criteria:

1. comprehensive standardisation of methodology
2. validated controls: the inclusion of a chromosome 17 control to allow for correction of the HER2 signal number for chromosome 17 aneusomy (seen in over 50% of cases) is considered beneficial by many laboratories and is recommended
3. validated scoring procedures.

General principles

There is no evidence that storage of blocks or slides leads to deterioration of signal. However, it is recommended that storage of cut sections from controls or samples for over 6–12 months should be avoided.

It is advisable to locate areas of invasive tumour using a serial section stained with haematoxylin and eosin (H&E) and to use this to locate tumour areas to be scored after testing. Care should be taken to avoid areas of ductal carcinoma in situ, which can show amplification even when adjacent invasive tumour cells are negative. With experience, such features can be identified under fluorescence microscopy, however the use of serial H&E sections is essential should there be any uncertainty in this area.

Tissue digestion should be standardised to maintain nuclear morphology and should follow strict protocols.¹⁶ Some laboratories find it helpful to evaluate nuclear structure before hybridisation and to adjust digestion, where appropriate, to preserve nuclear integrity. This may be particularly valuable with difficult sections, cytology samples, bone biopsies, etc. Evaluation of sections before hybridisation can also improve efficiency and is recommended. Hybridisation and washing steps should be standardised. Guidance can be provided by the reference laboratories. Use of automated tissue processors and standardised commercial tissue digestion kits can improve consistency and should be considered.

It is recommended that commercially available probes are used. For systems using in-house, nick translated probes, attention should be given to batch variability of nick translation enzymes, etc.

Laboratories not wishing to use in-house methods should consider using a commercial system such as PathVysion (Abbott Vysis). Other commercial systems currently available are not yet widely validated or lack the chromosome 17 control discussed above.

Scoring FISH

HER2 FISH testing results are conventionally expressed as the ratio of HER2 signal to chromosome 17 signal. Tumours showing a ratio >2 should be considered as positive. Cut off values for *HER2* gene amplification when chromosome 17 probes are not used have not been established.

The number of chromosome 17 and HER2 signals is scored for 20–60 cells, where possible using at least three distinct tumour fields, and the mean HER2 to chromosome 17 copy ratio is calculated. In most cases, where either clear amplification is observed or the ratio is below 1.5, scoring of 20 cells is sufficient. In cases where either tumour heterogeneity is seen (1–2% of cases) or the ratio is close to 2.0 (ratio of 1.5–2.3), more cells should be scored (up to 60). Samples with >2.0 copies of HER2 for each chromosome 17 are considered to be amplified. Published data suggest that interobserver variation is significantly lower for FISH than for IHC. However, especially when developing a new service, care needs to be taken. The recommendation is that laboratories should perform validation studies by dual observer scoring when training new staff until interobserver variation for normal specimens and those with

low level amplification is routinely below 15%. Continued monitoring of scoring offers advantages in quality control and training, but is not a requirement. Variation increases with highly amplified samples, and is not critical where the ratio exceeds 4.

Quality assurance

To ensure adequate quality assurance, UK laboratories wishing to set up independent FISH testing are recommended to join the proposed EQA scheme coordinated by NEQAS. Currently, we envisage using tissue microarrays or multiblocks to provide adequate material for analysis. The scheme will be designed to evaluate methodological and scoring aspects but may not cover morphological aspects.

References

1. Plunkett TA, Miles DW. New biological therapies for breast cancer. *International Journal of Clinical Practice*, 2002, 56: 261–266.
2. National Institute for Clinical Excellence. *Guidance on the Use of Trastuzumab for the Treatment of Advanced Breast Cancer 2002*. Technology Appraisal No. 34. <http://www.nice.org.uk/article.asp?a=29280>
3. Ellis IO, Dowsett M, Bartlett J et al. Recommendations for HER2 testing in the UK. *Journal of Clinical Pathology*, 2000, 53: 890–892.
4. Press MF, Hung G, Godolphin W et al. Sensitivity of HER2/neu antibodies in archival tissue samples: potential source of errors in immunohistochemical studies of oncogene expression. *Cancer Research*, 1994, 54: 2771–2777.
5. Walker R. The significance of histological determination of HER-2 status in breast cancer. *The Breast*, 2000, 9: 130–133.
6. Schnitt SJ. Breast cancer in the 21st century: Neu opportunities and neu challenges. *Modern Pathology*, 2001, 14: 213–218.
7. Wang S, Saboorian MH, Frenkel E et al. Laboratory assessment of the status of Her-2/neu protein and oncogene in breast cancer specimens: comparison of immunohistochemistry assay with fluorescence in situ hybridisation assays. *Journal of Clinical Pathology*, 2000, 53: 374–381.
8. Lehr H-A, Jacobs TW, Yaziji H et al. Quantitative evaluation of HER-2/neu status in breast cancer by fluorescence in situ hybridization and by immunohistochemistry with image analysis. *American Journal of Clinical Pathology*, 2001, 115: 814–822.
9. Rampaul RS, Pinder SE, Gullick WJ et al. HER-2 in breast cancer: methods of detection, clinical significance and future prospects for treatment. *Critical Reviews in Oncology and Hematology*, 2002, 43: 231–244
10. Paik S, Bryant J, Tan-Chiu E et al. Real-world performance of HER2 testing: National Surgical Adjuvant Breast and Bowel Project experience. *Journal of the National Cancer Institute*, 2002, 94: 852–854.
11. Roche PC, Suman VJ, Jenkins RB et al. Concordance between local and central laboratory HER2 testing in the breast intergroup trial N9831. *Journal of the National Cancer Institute*, 2002, 94: 855–857.
12. Dowsett M, Ellis IO, Bartlett JMS et al. Correlation between immunohistochemistry and FISH for HER-2 in 441 breast carcinomas from multiple hospitals. *Journal of Pathology*, 2001, 195: supplement 5A.
13. Rhodes A, Jasani B, Couturier J et al. A formalin-fixed, paraffin-processed cell line standard for quality control of immunohistochemical assay of HER-2/neu expression in breast cancer. *American Journal of Clinical Pathology*, 2002, 117: 81–89.

14. Rhodes A, Jasani B, Anderson E et al. Evaluation of HER-2/neu immunohistochemical assay sensitivity and scoring on formalin fixed and paraffin processed cell lines and breast carcinomas: a comparative study involving results from laboratories in 21 countries. *American Journal of Clinical Pathology*, 2002, 118: 408–417.
15. Mass R. The role of Her-2 expression in predicting response to therapy in breast cancer. *Seminars in Oncology*, 2000, 27: 46–52.
16. Watters AD, Bartlett JM. Fluorescence in situ hybridization in paraffin tissue sections: pretreatment protocol. *Molecular Biotechnology*, 2002, 21: 217–220.

Reproduced with permission from the BMJ Publishing Group from the *Journal of Clinical Pathology*, 2004, 57: 233–237.

APPENDIX 7: QUALITY ASSURANCE FOR OESTROGEN RECEPTORS AND PROGESTERONE RECEPTORS

Writing party

Dr A Rhodes, Dr B Jasani

All clinical laboratories utilising assays for oestrogen receptors (ER) and progesterone receptors (PR) as predictive or prognostic tests must participate in an appropriate external quality assurance (EQA) programme such as that run by the UK National External Quality Assessment Scheme for Immunocytochemistry (UK NEQAS-ICC).¹

UK NEQAS-ICC on a quarterly basis circulates to over 200 laboratories unstained formalin fixed and paraffin processed tissue sections from a composite block comprising tissue fragments of known receptor content, eg typically comprising receptor rich, receptor poor and receptor negative invasive breast carcinomas. Participating laboratories are requested to test the UK NEQAS section and their own in-house control for ER or PR and to return them to the organising centre for evaluation by a panel of four expert assessors. Each of the four assessors awards marks out of 5, which are then totalled to give a score out of 20. An acceptable score (> 12) is given when the expected proportion of invasive tumour nuclei is clearly stained with the expected staining intensity. A borderline score of 10–12 indicates that, although the staining has achieved the minimum cut off for receptor positive tumours, less than the expected proportion of invasive nuclei is clearly demonstrated. Lastly, a score of < 10 is given when considerably fewer invasive nuclei than expected are stained. In such instances, this is frequently below a recognised minimum cut off point used to define receptor positivity, eg < 10% of invasive tumour cells stained.

In order to identify and remedy suboptimal performance for immunohistochemistry (IHC) receptor assays by UK laboratories within an acceptable time frame, the following procedure will be adopted. Laboratories achieving scores of < 10 on in-house sections will be issued a warning letter and offered technical advice for improvement. This will include attendance at the UK NEQAS organiser's laboratory by the poorly performing laboratory's biomedical scientist. A score of < 10 on in-house sections on a second occasion within the same fiscal year will result in the laboratory concerned being removed from the UK NEQAS for Hormonal Receptors module register. In addition, the UK NEQAS-ICC will approach all UK laboratories achieving a score < 13 on UK NEQAS or in-house sections and provide advice for improvement. Any of these participating laboratories subsequently achieving a score < 13 at the next two subsequent assessment runs on UK NEQAS or in-house sections will be issued a warning letter. With this, UK NEQAS will provide further technical advice and support to include attendance at the UK NEQAS organiser's laboratory by the poorly performing laboratory's biomedical scientist. All attempts will be made to assist the laboratory to improve. Failure to do so (ie laboratory accruing a total of four successive scores

< 13 on the UK NEQAS or in-house sections) will result in the laboratory concerned being removed from the UK NEQAS for Hormonal Receptors module register.

The overall approach will aim to ensure that very poorly performing laboratories (ie those scoring <10 on in-house material) are identified immediately and given an urgent warning and help to improve their performances within a 6 month period. Laboratories producing borderline performance (scores of < 13 on UK NEQAS or in-house material) will be given no more than 12 months to show a consistent improvement in their performance to an acceptable standard. Failure to improve on either account within the designated period will result in the laboratory being removed from the UK NEQAS-ICC for Hormonal Receptors participation register.

Reference

1. Rhodes A, Jasani B, Balaton AJ et al. Study of interlaboratory reliability and reproducibility of estrogen and progesterone receptor assays in Europe: documentation of poor reliability and identification of insufficient microwave antigen retrieval time as a major contributory element of unreliable assays. *American Journal of Clinical Pathology*, 2001, 115: 44–58.

APPENDIX 8: QUALITY ASSURANCE FOR HUMAN EPIDERMAL GROWTH FACTOR RECEPTOR 2 (HER2) IMMUNOHISTOCHEMICAL ASSAYS

Writing party

Dr A Rhodes, Dr B Jasani

All clinical laboratories utilising assays for HER-2/neu as predictive or prognostic tests must participate in an appropriate external quality assurance (EQA) programme such as that run by the UK National External Quality Assessment Scheme for Immunocytochemistry (UK NEQAS-ICC).

UK NEQAS-ICC on a quarterly basis circulates to over 100 laboratories unstained sections from a formalin fixed and paraffin processed block comprising the human breast carcinoma cell lines MDA-MB-453, BT-20 and MCF-7 and the ovarian carcinoma cell line SKOV-3. Previous FISH analysis on these cell lines showed the SKOV-3 and MDA-MB-453 cell lines to have *HER-2/neu* gene amplification, whereas the cell lines BT-20 and MCF-7 do not.¹ With appropriate assay sensitivity, the cell line SKOV-3 stains unequivocally positive (3+) and the cell lines MCF-7 and BT-20 stain unequivocally negative (0 or 1+). The most appropriate result on the cell line MDA-MB-453 is 2+. Following strict adherence to the Dako HercepTest staining protocol, it has been shown that over 80% of laboratories using the HercepTest achieve this permutation of immunostaining on the cell lines SKOV-3, MDA-MB-453, BT-20 and MCF-7. Laboratories using individually customised assays employing the clones CB11 and TAB 250 and Dako polyclonal antisera have achieved equivalent staining.

Participating laboratories are requested to test the UK NEQAS sections and their own in-house control for HER-2/neu and to return them to the organising centre for evaluation by a panel of five expert assessors using the method of evaluation initially devised for the Clinical Trials Assay, with the median value from the five assessors being taken as the final score.¹⁻³

In order to identify and rectify suboptimal performance for HER-2/neu assays by UK laboratories within an acceptable time frame, UK NEQAS-ICC will approach all UK laboratories achieving an inappropriate result on the UK NEQAS sections and provide advice for improvement. Any of these participating laboratories subsequently achieving an inappropriate result at two subsequent assessments on the UK NEQAS sections will be issued a warning letter. With the issue of this warning letter, UK NEQAS will provide further technical advice and support. This will include attendance at the UK NEQAS organiser's laboratory by the poor performing laboratory's biomedical scientist. All attempts will be made to assist the laboratory to improve. Failure to do so, however, with the laboratory accruing a total of four successive inappropriate scores on the UK NEQAS sections despite intensive advice and assistance, will result

in the laboratory concerned being removed from the UK NEQAS for HER-2/neu register. This approach will ensure that poorly performing laboratories are identified immediately and the situation rectified within a 12 month period, either by the laboratories showing improvement to an acceptable standard or by them being removed from the UK NEQAS participation register.

References

1. Rhodes A, Jasani B, Couturier J et al. A formalin fixed and paraffin processed cell line standard for quality control of immunohistochemical assay of HER-2/neu expression in breast cancer. *American Journal of Clinical Pathology*, 2002, 117: 81–89.
2. Ellis IO, Dowsett M, Bartlett J et al. Recommendations for HER2 testing in the UK. *Journal of Clinical Pathology*, 2000, 53: 890–892.
3. Mass R. The role of HER-2 expression in predicting response to therapy in breast cancer. *Seminars in Oncology*, 2000, 27: 46–52.

APPENDIX 9: NOTTINGHAM PROGNOSTIC INDEX

For an individual patient, prediction of prognosis is improved by assessment and a combination of time dependent and biological factors in the form of a prognostic index. Lymph node stage, histological grade and tumour size have the greatest importance in predicting invasive tumour behaviour and have been combined to form the Nottingham Prognostic Index (NPI).^{1,2} Results have been confirmed in prospective series and other centres.³⁻⁵

Appropriate weighting from multivariate analysis has given the following formula for this prognostic index:

$0.2 \times \text{tumour size (cm)} + \text{lymph node stage (1, 2 or 3)} + \text{histological grade (1, 2 or 3)}$

where lymph node stage 1 is node negative; stage 2 is three or fewer nodes containing metastatic carcinoma; stage 3 is four or more nodes involved, or apical node or any axillary plus internal mammary node.

For multiple invasive foci or synchronous tumours, the highest grade lesion (and its size) will be used for the NPI calculation. If of the same grade, the size of the largest invasive focus is utilised. The higher the NPI score the worse the prognosis. The NPI can be used for selection of therapy for each patient rather than basing the choice of treatment on any single prognostic factor. Patients with an NPI score of 3.4 or less have a good prognosis, and those with an NPI score of 3.0 or less have an equivalent survival to age-matched controls (3% annual mortality). Women with an NPI of greater than 5.4 have a poor prognosis, and may wish to receive more aggressive adjuvant therapy. Choice of adjuvant treatment for patients with an NPI score between 3.4 and 5.4 is dependent on other variables such as hormone receptor status and the patient's general state of health.

References

1. Haybittle JL, Blamey RW, Elston CW et al. A prognostic index in primary breast cancer. *British Journal of Cancer*, 1982, 45: 361–366.
2. Galea MH, Blamey RW, Elston CE, Ellis IO. The Nottingham Prognostic Index in primary breast cancer. *Breast Cancer Research Treatment*, 1992, 22: 207–219.
3. Brown JM, Benson EA, Jones M. Confirmation of a long-term prognostic index in breast cancer. *Breast*, 1993, 2: 144–147.
4. Balslev I, Axelsson CK, Zedelev K et al. The Nottingham Prognostic Index applied to 9,149 patients from the studies of the Danish Breast Cancer Cooperative Group (DBCG). *Breast Cancer Research Treatment*, 1994, 32: 281–290.
5. Sundquist M, Thorstenson S, Brudin L, Nordenskjold B. Applying the Nottingham Prognostic Index to a Swedish breast cancer population. South East Swedish Breast Cancer Study Group. *Breast Cancer Research Treatment*, 1999, 53: 1–8.

APPENDIX 10: SUGGESTED SNOMED CODES FOR BREAST PATHOLOGY

1. Topography

Breast	T04000
Male breast	T04040
Nipple	T04100
Axilla	TY81001

Note Axilla includes clearance, dissection, node sampling and sentinel node biopsy.

2. Procedure codes

Mastectomy	P11000A
Breast reduction specimen	P11000J
Wide local excision	P11000B (including wedge and segmental excision, ie therapeutic procedures)
Open biopsy	P11000C
Needle core biopsy	P11000G
Localisation biopsy	P11000D
Re-excision specimen	P11000E
Cavity biopsy	P11000F (including shave biopsies, etc)
Axillary surgery	P11000H
Mammotome specimen	P11000H

Note Agreement has yet to be reached on procedure codes; however, in the interim it is suggested that local codes are adopted to enable differentiation of breast surgery specimens. The codes indicated are a suggested interim proposal acknowledging that, at a future date, these codes will probably be changed when there is a national, agreed system of coding. Also note that this procedure list is not exhaustive.

Unusual case for review/audit	P0354
Photomicrography: good example	P3239
Teaching case: good example	P0218
Consult case: detailed review	P3085

3. Morphology codes

Abscess NOS	M41740
Accessory/ectopic breast	M26030
Adenocarcinoma NOS (see carcinoma)	M81403
Adenoma ductal	M85030
Adenoma nipple	M85060
Adenoma pleomorphic	M89400
Adenoma tubular	M82110
Adenosis blunt duct	M74240
Adenosis microglandular	M72480
Adenosis sclerosing	M74220
Adenomyoepithelioma/myoepithelioma benign	M89820
Adenomyoepithelioma malignant	M89823
Angiosarcoma	M91203
Apocrine metaplasia	M73310
Apocrine atypia	M73315
Carcinoma ductal in situ NOS	M85002
Apocrine DCIS	M85732
Neuroendocrine DCIS	M82402

Pathology Reporting of Breast Disease

Carcinoma papillary in situ/encysted	M82602
Carcinoma lobular in situ	M85202
Carcinoma adenoid cystic	M82003
Carcinoma adenosquamous	M85603
Carcinoma apocrine	M85733
Carcinoma clear cell	M83103
Carcinoma cribriform	M83013
Carcinoma infiltrating ductal/NST	M85003
Carcinoma infiltrating lobular	M85203
Carcinoma medullary	M85103
Carcinoma metaplastic	M80333
Carcinoma metastatic	M80106
Carcinoma microinvasive	M80715
Carcinoma mixed (specify subtypes separately)	
Carcinoma inflammatory	M85303
Carcinoma invasive micropapillary	M85033
Carcinoma mucinous	M84803
Carcinoma mucoepidermoid	M84303
Carcinoma myoepithelial	M85623
Carcinoma neuroendocrine	M82403
Carcinoma papillary invasive	M82603
Carcinoma secretory	M85023
Carcinoma signet ring	M84903
Carcinoma spindle cell	M80323
Carcinoma tubular	M82113
Carcinoma tubular mixed	M85213
Carcinoma undifferentiated	M80203
Calcification	M55400
Carcinoid tumour	M82401
Chemotherapy effect	F53812
Collagenous spherulosis	M50052
Columnar cell atypia	M67020
Complex sclerosing lesion	M49060
Cyst NOS	M33403
Duct ectasia	M32100
Excision margins tumour free	M09400
Fat necrosis	M54110
Fibroadenoma NOS	M90100
Fibroadenoma juvenile	M90300
Fibroadenomatoid hyperplasia	M90300
Fibrocystic change	M74320
Fibromatosis	M76100
Fistula	M39300
Focal lactational change	M69880
Foreign body reaction	M44140
Galactocoele	M33220
Gynaecomastia (T04040)	M71000
Juvenile hypertrophy	M71110
Hamartoma	M75500
Haemangioma	M91200
Hyperplasia atypical columnar cell	M57020
Hyperplasia atypical ductal	M72175

Pathology Reporting of Breast Disease

Hyperplasia atypical lobular	M72105
Hyperplasia cystic hypersecretory	M72060
Hyperplasia microglandular	M72450
Hyperplasia stromal NOS & PASH	M72430
Hyperplasia usual epithelial (ductal)	M72170
Inflammation acute	M41000
Inflammation chronic	M43000
Inflammation granulomatous	M44000
Infarction	M54700
Involutional atrophy	M58160
Involutional change	M70800
Lactation	F31920
Lipoma	M88500
Lymphoma (extranodal)	M95903
Lymphocytic lobulitis sclerosing	D47000
Metaplasia epithelial (clear cell, etc)	M73200
Metaplasia atypical	M73005
Metaplasia chondroid	M73600
Metaplasia osseous	M73400
Metaplasia squamous	M73220
Morphological description only	M09350
Mucocoele-like lesion	M36240
Myofibroblastoma	M88900
Nodular fasciitis	M76130
Normal: NOS	M00100
Normal: infant/sexual immaturity	F97400
Paget's disease of nipple (T04100)	M85403
Papilloma ductal	M85030
Papilloma multiple	M85050
PASH	M72430
Phyllodes tumour NOS	M90201
Phyllodes benign	M90200
Phyllodes malignant	M90203
Plasma cell mastitis	M43060
Pregnancy	M69880
Radial scar	M49060
Radiotherapy effect	M11600
Silicone	E5911
Solitary fibrous tumour	M88100
Surgical wound or cavity	M14020
Syringoma	M84070
Weddelite	M55400

NOS, not otherwise specified; DCIS, ductal carcinoma in situ; NST, no specific/special type; PASH, pseudoangiomatous stromal hyperplasia.

Reproduced with permission. The College of American Pathologists (CAP) owns the copyright in SNOMED and SNOMED CT, the trademarks SNOMED and SNOMED CT, and patent rights in SNOMED and SNOMED CT. NHS end-users have no rights to supply or sell copies of SNOMED CT or the browser in any format to others.